

Clinical Effectiveness Protocols for Imaging in the Management of Ureteral Calculous Disease: AUA Technology Assessment

Pat Fox Fulgham,^{*,†} Dean G. Assimos,^{*} Margaret Sue Pearle and Glenn M. Preminger

From the Texas Health Presbyterian Hospital of Dallas (PFF) and University of Texas Southwestern Medical Center (MSP), Dallas, Texas; Wake Forest University School of Medicine, Winston-Salem (DGA), and Duke University Medical Center, Durham (GMP), North Carolina

Purpose: This technology assessment addresses the optimal use of imaging in the evaluation and treatment of patients with suspected or documented ureteral stones.

Materials and Methods: A comprehensive literature search addressing 4 guiding questions was performed for full text in English articles published between January 1990 and July 2011. The search focused on major subtopics associated with the imaging of ureteral calculi, and included specific imaging modalities used in the diagnosis and management of ureteral calculous disease such as unenhanced (noncontrast) computerized tomography, conventional radiography, ultrasound, excretory urography, magnetic resonance imaging and nuclear medicine studies. Protocols (in the form of decision tree algorithms) were developed based on this literature review and in some instances on panel opinion. The 4 questions addressed were 1) What imaging study should be performed for suspected ureteral calculous disease? 2) What information should be obtained? 3) After diagnosis of a ureteral calculus, what followup imaging should be used? 4) After treatment of a ureteral calculus, what followup imaging studies should be obtained?

Results: Based on these protocols, noncontrast computerized tomography is recommended to establish the diagnosis in most cases, with a low energy protocol advocated if body habitus is favorable. Conventional radiography and ultrasound are endorsed for monitoring the passage of most radiopaque stones as well as for most patients undergoing stone removal. Other studies may be indicated based on imaging findings, and patient, stone and clinical factors.

Conclusions: The protocols generated assist the clinician in establishing the diagnosis of ureteral calculous disease, monitoring stone passage and following patients after treatment. The protocols take into account not only clinical effectiveness but also cost-effectiveness and risk/harm associated with the various imaging modalities.

Key Words: ureteral calculi, clinical protocols, diagnostic imaging

IMAGING for urinary calculous disease or the symptoms and signs associated with renal calculous disease accounts for a significant portion of all imaging performed by urologists.¹ Patients with suspected ureteral calculi often

undergo repeated imaging studies before, during and after treatment. Furthermore, because patients with urinary calculous disease are at high risk for recurrence, repeat imaging is common.² Imaging accounts for 16%

Abbreviations and Acronyms

BMI = body mass index
 CT = computerized tomography
 hydro = hydronephrosis
 IV = intravenous
 IVP = excretory urography
 KUB = plain x-ray of the kidneys, ureters and bladder
 MET = medical expulsive therapy
 NCCT = noncontrast computerized tomography
 sono = ultrasonography
 SWL = shock wave lithotripsy

Accepted for publication October 11, 2012.

* Funding of the committee was provided by the AUA and Committee members received no remuneration for their work. Each member of the committee provides an ongoing conflict of interest disclosure to the AUA. All panel members completed COI disclosures. Relationships that have expired (more than 1 year old) since the panel's initial meeting are listed. Those marked with (C) indicate that compensation was received and relationships designated by (U) indicate no compensation was received. Consultant/Advisor: Dean Assimos, Oxalosis and Hyperoxaluria Foundation (U); Scientific Study or Trial: Dean Assimos, National Institutes of Health (C); Other-Investment Interest: Pat F. Fulgham, Urology Clinics of North Texas (C); Other-Health Publishing: Dean Assimos, Med Review in Urology (C), Urology Times (C); Partnership: Piedmont Stone (C).

† Correspondence: Department of Urology, Texas Health Presbyterian Dallas, Dallas, Texas 75231 (e-mail: pfulgham@airmail.net).

Editor's Note: This article is the first of 5 published in this issue for which category 1 CME credits can be earned. Instructions for obtaining credits are given with the questions on pages 1608 and 1609.

of the total expenditure for each episode of care in the management of urinary calculous disease.³

The EAU (European Association of Urology)-AUA (American Urological Association) Clinical Guidelines for the Management of Ureteral Calculi cover the evidence for clinical recommendations for the management of ureteral calculous disease.⁴ The American College of Radiology Appropriateness Criteria® document performance characteristics of various imaging studies for a given clinical scenario.⁵ However, neither document addresses critical questions about how imaging technology should be used to maximize its effectiveness in the treatment of patients with suspected or documented ureteral stones. This need served as the impetus for the generation of this document.

Noncontrast computerized tomography has emerged as the most sensitive and specific modality for detecting ureteral calculi. Therefore, CT is frequently used in the initial diagnosis of ureteral calculous disease,⁶ and to a lesser extent in the followup of known ureteral calculi before and after treatment. Protocols guiding imaging use in the management of ureteral calculous disease are desirable because of the potentially harmful cumulative effects of radiation exposure to patients and the increased cost of high resolution axial imaging modalities.

There were 4 questions that provided the framework for the generation of the protocols in this document. 1) What imaging study should be performed for suspected ureteral calculous disease? 2) What information should be obtained? 3) Once a ureteral calculus has been diagnosed, what imaging modality should be used? 4) After treatment of a ureteral calculus, what followup imaging studies should be obtained?

Current research fails to provide objective evidence to support the answers to some of these questions about imaging. When objective evidence does not exist, the most effective course of action is the one that 1) has a reasonable probability of answering the clinical questions at hand, 2) causes the least potential harm and 3) is cost-effective.

This Technical Assessment was developed to complement the EAU-AUA Clinical Guideline for the Management of Ureteral Calculi.⁴ Methodology similar to that used in the development of AUA Guidelines was used in the development of this technical assessment. Unlike the Guidelines, these protocols are based on clinical outcomes and consideration of the potential harm and cost-effectiveness of each approach. The clinical judgment of the physician and the preferences and expectations of the patient should continue to be the main determinants for the appropriate management of ureteral calculi. Practical considerations regarding the availability of im-

aging modalities in a given environment may influence the choice of imaging study. However, of note, imaging is merely a tool to support clinical decisions.

To assist the clinician, decision tree algorithms have been developed to select the most effective imaging study for a given clinical scenario. The scenarios are divided into 1) initial presentation, 2) followup or surveillance of a known ureteral calculus and 3) followup after treatment or passage of a ureteral calculus.

In summary, the protocols were developed specifically to support clinicians in decision making for a common clinical condition. These protocols are intended to enhance the effective use of imaging for suspected or proven ureteral calculous disease by urologists, emergency physicians and primary care physicians.

METHODOLOGY PROTOCOL AND LITERATURE SEARCH

To assist in the development of these clinical effectiveness protocols, the panel crafted 31 guiding questions classified by index patient, specific modality and other factors. A comprehensive search of the literature related to these guiding questions was performed for full text in English articles published between January 1990 and July 2011, and was targeted toward major subtopics associated with the imaging of ureteral calculi. (See Appendix A of the full-text assessment for a full explanation of methodology and findings at http://www.auanet.org/content/media/imaging_assessment.pdf.)

INITIAL PRESENTATION

Patients who are suspected of having a ureteral stone frequently experience severe flank and occasionally abdominal pain. Noncontrast CT is the preferred initial imaging study for the index patient (Level A Evidence). This selection is based on the reported median sensitivity and specificity for NCCT in the detection of ureteral calculi as 98% and 97%, respectively, far superior to other imaging modalities. Based on a review of the literature, there appears to be consensus that the upper threshold for low dose CT is 4 mSv. Low dose CT is preferred for patients with a BMI of 30 kg/m² or less as this modification to standard CT imaging limits the potential long-term side effects of ionizing radiation while maintaining sensitivity and specificity at 90% or greater.⁷⁻⁹ However, low dose CT is not recommended for those with a BMI greater than 30 kg/m² due to the lower sensitivity and specificity for detecting ureteral stones.

Figure 1. Initial presentation (decision tree diagram 1)

When a ureteral calculus is demonstrated on CT, the stone is also identifiable on CT scout approximately 50% of the time.¹⁰ A CT scout film is performed at a lower mA than a standard kidney, ureter, bladder film, accounting in part for the decreased sensitivity in detecting stones. Standard KUB should be performed when the stone is not demonstrated on the CT scout as the stone will be seen in 10% of these patients.^{10,11} Followup KUB is obtained in those who are candidates for observation and in whom the stone was identified on the CT scout or initial KUB as it serves as an indicator of stone progression. A followup KUB should also be considered in those in whom the stone was not seen on the initial CT scout or KUB because it was positioned in the sacroiliac area, thus limiting its visualization. Oblique films may also be considered in such cases, either at the time of the original CT or at followup, as these images may further facilitate stone visualization (fig. 1).

Certain parameters and findings should be assessed on CT imaging to facilitate subsequent management decisions. The majority of patients with ureteral stones will have some degree of hydrone-

phrosis, a mean of 83% based on our review of 48 studies. However, the presence of hydronephrosis does not predict the need for intervention.¹² The presence or the degree of hydronephrosis has been shown to influence results with shock wave lithotripsy of ureteral stones, but this has less impact on ureteroscopic removal.¹³⁻¹⁹

Alternative imaging modalities are considered for specific patient groups. The combination of renal ultrasonography and KUB is a viable option for a known stone former who has previously had radiopaque stones. Sensitivities of 58% to 100% and specificities of 37.2% to 100% have been reported for this combination of modalities (Level C Evidence).²⁰⁻²⁶

Renal ultrasonography, despite its lower sensitivity, is the preferred initial imaging modality for children because of radiation concerns.²⁷ Low dose CT is a consideration if renal ultrasonography is not diagnostic for children in whom a ureteral stone is suspected.^{28,29} Renal ultrasonography is the initial imaging modality of choice for pregnant patients with suspected colic.³⁰⁻³⁶ If the diagnosis is not established with this study during the first trimester, magnetic resonance imaging without contrast should be

considered as second line imaging as the fetus is most susceptible to potential radiation induced injury in the first trimester. Women in the second and third trimesters are candidates for low dose CT if ultrasonography is not diagnostic.³⁷ An American College of Obstetricians and Gynecologists committee on obstetric practice endorses the use of low dose CT when clinically indicated and notes that an exposure of less than 5 rads, a threshold well above the average for a low dose CT, is not associated with the development of fetal anomalies or fetal loss.³⁸

OBSERVATION OF KNOWN URETERAL CALCULUS

The chance of spontaneous passage of a known ureteral calculus is based primarily on stone size and location. Perhaps the best study investigating the natural history of a known ureteral calculus demonstrated that 83% of patients will pass their stone without the need for intervention.³⁹ One of the more important aspects of this study was the observation that among the stones that passed spontaneously, 95% passed within 6 weeks of followup.

The EAU-AUA Guideline on the Management of Ureteral Calculi suggests as an Option that medical expulsive therapy should be considered as first line treatment for most patients with ureteral stones whose symptoms are controlled. As a Standard, the Guidelines recommend that patients “should be followed with periodic imaging studies to monitor stone position and to assess for hydronephrosis.”⁴

The Panel sought to validate the reliability of hydronephrosis as a proxy for the degree of obstruction in patients with suspected ureteral calculi. In particular, if hydronephrosis is present with a known ureteral calculus, what is the best way to assess obstruction or the potential for loss of renal function? The majority of these studies used IVP to assess renal obstruction/function (see evidence report in Appendix B, available at http://www.auanet.org/content/media/imaging_evidence_report.pdf). There was a distinct paucity of studies on the use of nuclear renography to determine obstruction in this setting. Of note, differences in threshold parameters used to classify obstruction in these studies contributed to the variability in the reported sensitivity and specificity.

The quality of the body of evidence regarding the followup of a ureteral calculus is low (Level C Evidence). The Panel took into account not only the sensitivity/specificity of various imaging modalities in determining their ability to follow known ureteral calculi, but also assessed the impact of radiation exposure and costs of the imaging studies when making their recommendations. Based on these studies and

expert Panel opinion, a decision tree diagram and recommendations are offered (fig. 2).

After a period of MET in a patient with a known radiopaque ureteral calculus less than 10 mm in diameter with minimal to moderate associated hydronephrosis and no evidence of renal damage, assuming the symptoms are well controlled, the Panel believes that ultrasonography combined with plain KUB offers the best combination of sensitivity/specificity with minimal radiation exposure and significantly reduced cost compared to NCCT imaging. In patients who continue to have symptoms without evidence of stone passage, the ultrasonography/KUB combination can assess stone progression as well as ongoing hydronephrosis. However, if ultrasonography and KUB fail to demonstrate hydronephrosis or persistent stone, further imaging with plain radiographs or low dose NCCT limited to the area of interest may be warranted to definitively ascertain the continued presence of the stone.

In those patients with a radiolucent stone, low dose NCCT can assess stone progression and the degree of hydronephrosis. Clinical acumen combined with new findings on imaging studies will assist the clinician in determining whether continued observation combined with MET or surgical intervention is warranted. It may be reasonable to consider confirmatory radiographic imaging before surgical intervention.

FOLLOWUP URETERAL CALCULUS AFTER TREATMENT

After definitive surgical intervention for a ureteral calculus, followup imaging is obtained to assure complete stone removal and/or the absence of obstruction. Ureteral instrumentation and particularly stone fragmentation warrant postoperative imaging to document 1) the clearance of the stone/fragments, 2) the resolution of hydronephrosis and/or 3) the development of unanticipated obstruction such as that from ureteral stricture. Although the incidence of ureteral stricture after ureteroscopy is low (1% to 4%), its occurrence is not entirely predictable.^{4,40} Ureteral stricture formation after SWL is distinctly uncommon (0% to 2%)^{4,40} and in most reports is likely the result of adjunctive instrumentation (ureteral catheterization, stone push-back) or stone impaction. However, after SWL the passage of fragments and resolution of associated obstruction should be confirmed.

Although the need for an imaging study to confirm stone/fragment clearance after SWL or ureteroscopy with lithotripsy is widely accepted, the need for followup studies in asymptomatic patients to assess for obstruction is subject to debate. At the center of the controversy is the reliability with which symptoms predict obstruction. Weizer et al reviewed

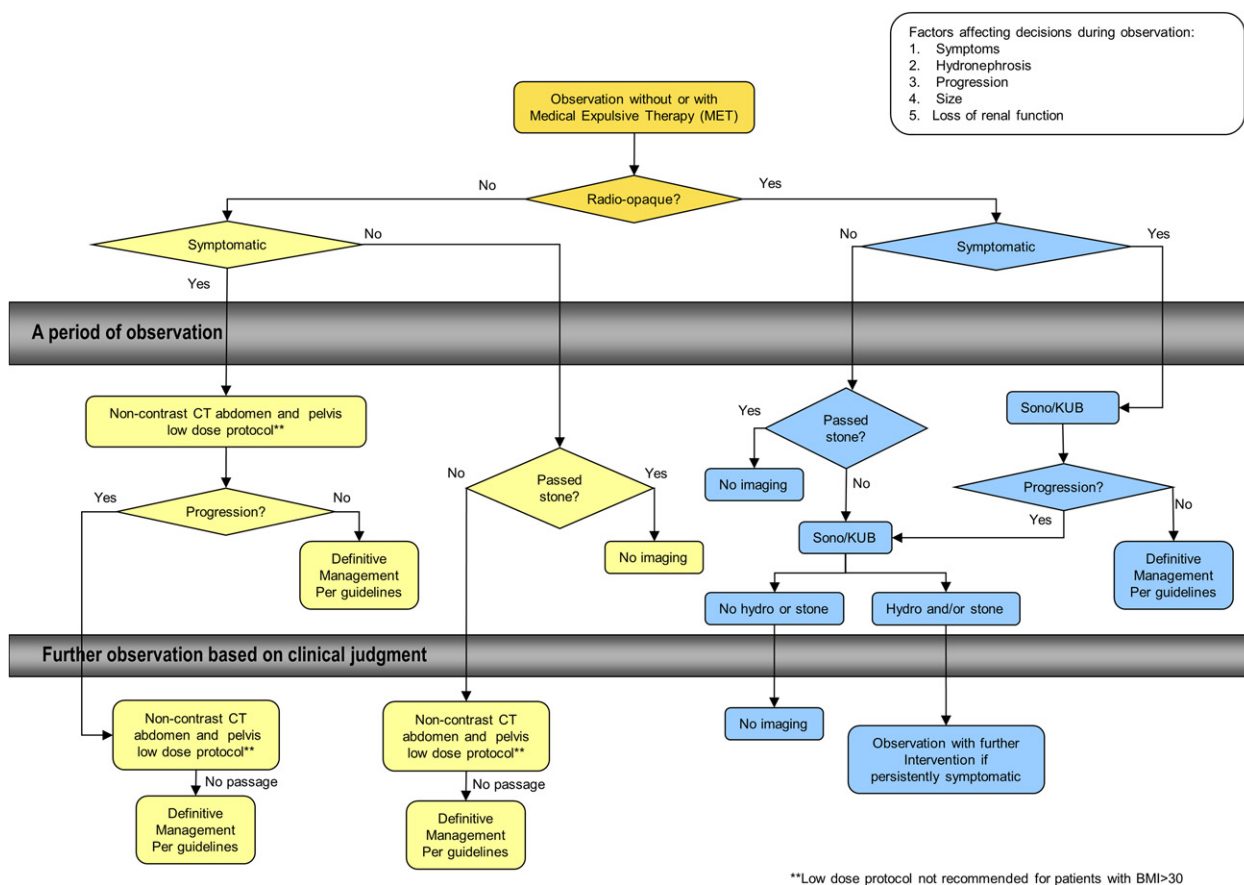


Figure 2. Observation of known ureteral calculus (decision tree diagram 2)

241 patients at a mean of 5.4 months after ureteroscopy using NCCT, renal ultrasound, IVP, diuretic renography or retrograde pyelogram.⁴⁰ Of 188 patients with no pain at postoperative followup, 7 (3.7%) nonetheless had obstruction on postoperative imaging studies. Bugg et al also reviewed 118 patients who underwent 143 ureteroscopic procedures, and were evaluated with IVP, renal ultrasound or CT at a mean of 7 months postoperatively.⁴¹ Among 77 patients with complete followup who were treated for renal or ureteral calculi, 1 of 25 (4%) without preoperative obstruction who reported resolution of their symptoms postoperatively was found to have persistent obstruction. Karadag et al identified silent obstruction in only 1 of 228 asymptomatic patients (0.4%) in their review of 268 patients undergoing ureteroscopy for calculi who underwent imaging with IVP at 3 months after ureteroscopy.⁴² Finally, Karod et al found no cases of silent obstruction among 183 patients who underwent ureteroscopy and were evaluated radiographically at a mean of 73 days postoperatively.⁴³

From these studies, it is clear that the incidence of postoperative obstruction in asymptomatic patients is decidedly low (Level C Evidence). According

to Bugg et al, among the select group of patients without postoperative pain or preoperative obstruction, 25 radiographic studies would be required to diagnose 1 case of persistent obstruction.⁴¹ Although seemingly a small price to pay to avoid the loss of 1 renal unit, this need-to-treat value is hardly justifiable from a strictly economic viewpoint. Nonetheless, the Panel believes that the relatively low cost and lack of ionizing radiation associated with renal sonography justify its use in the routine followup of patients treated for ureteral calculi.⁴⁰

Obstruction with or without associated symptoms after ureteroscopy is generally due to obstructing stone fragments or ureteral stricture. With the low incidence of stricture (less than 1% in most series), obstructing fragments are likely to comprise the more common etiology overall and may be detectable with KUB if radiopaque, thereby providing a means to identify patients who require further functional imaging and/or further treatment. In the future, perhaps with further subgroup analysis, perioperative patient or stone characteristics can be identified in those patients without obvious persistent stones who should undergo a functional imaging study or renal ultrasound. Based on current data and panel

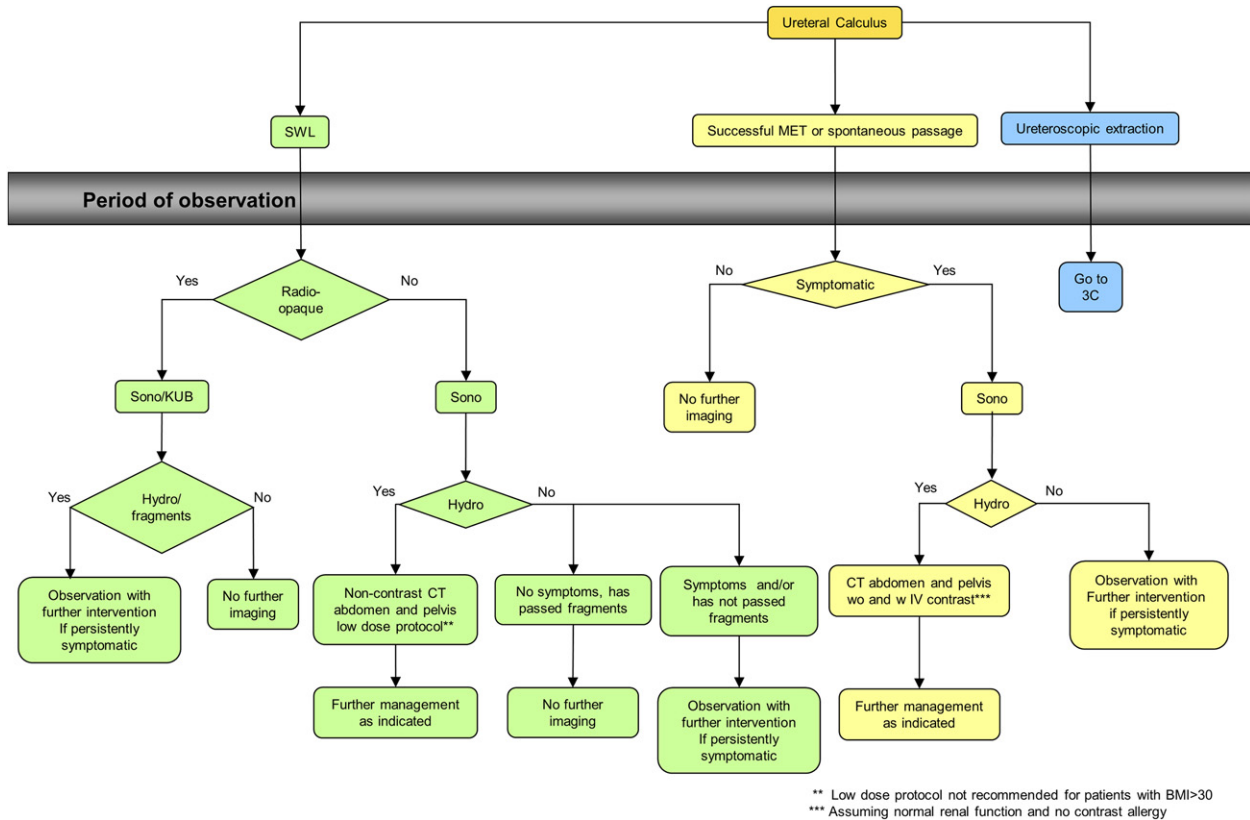


Figure 3. Followup of ureteral calculus after treatment (decision tree diagram 3)

opinion, we offer a decision tree diagram for the followup of ureteral calculi after treatment with MET or surgical intervention (SWL and ureteroscopy) (fig. 3).

For patients undergoing MET for a ureteral calculus in whom there is documented stone passage (stone in hand) and resolution of symptoms, no further imaging is necessary. If the patient remains symptomatic despite documented passage, evaluation with a renal sonogram will demonstrate whether persistent obstruction is present and will indicate the need for further imaging to identify an additional stone, residual edema or obstruction.

For patients undergoing SWL, followup renal sonogram with KUB for radiopaque stones or without KUB for radiolucent stones will document stone clearance and demonstrate the presence or absence of hydronephrosis (fig. 3). If the patient is asymptomatic and KUB/sonogram shows no stones or hydronephrosis, no further imaging is required. If KUB/sonogram demonstrates hydronephrosis and/or residual fragments, further observation with repeat imaging or secondary treatment is indicated. Patients with radiolucent stones and no hydronephrosis who remain symptomatic and/or have not passed fragments should be further observed with repeat imag-

ing (low dose NCCT) or intervention as indicated (fig. 3).

For patients undergoing ureteroscopy, the decision tree diagram distinguishes patients who undergo intact stone removal from those requiring stone fragmentation because of differing imaging requirements to document residual stones. For patients who undergo intact stone removal and whose symptoms have resolved, a renal sonogram is sufficient to document resolution of hydronephrosis (fig. 4). For symptomatic patients with or without hydronephrosis or asymptomatic patients with hydronephrosis on renal sonogram, CT of the abdomen and pelvis without and with contrast will determine the presence and/or site of obstruction, with further treatment dictated by the findings.

For patients who underwent ureteroscopy with stone fragmentation and who are asymptomatic, followup imaging with a sonogram (radiolucent stones) or a sonogram/KUB (radiopaque stones) will document the presence of residual fragments and/or hydronephrosis (fig. 5). In the absence of hydronephrosis and residual fragments, no further imaging is indicated. However, in patients with radiopaque stones, if residual fragments and/or hydronephrosis are documented, further observation or intervention

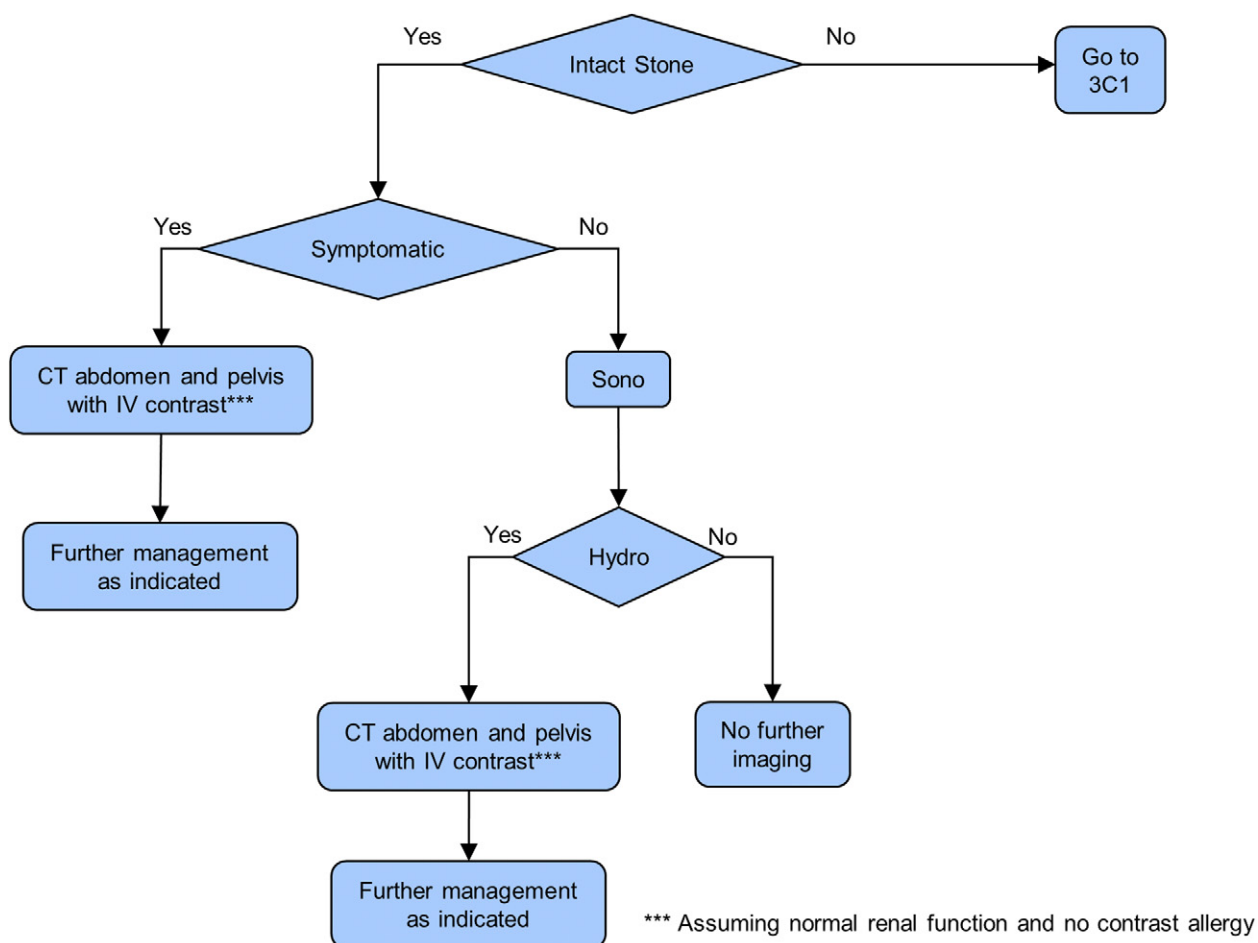


Figure 4. Followup after ureteroscopic extraction, intact stone (decision tree diagram 3C)

is pursued at the discretion of the practitioner. For patients with nonopaque stones, hydronephrosis on sonogram should prompt further evaluation with low dose NCCT to identify obstructing residual fragments.

In symptomatic patients with radiopaque stones, a sonogram and KUB also provide sufficient initial imaging to guide the need for further observation, interval imaging or secondary treatment as indicated. However, for those with radiolucent stones, low dose NCCT will optimally identify residual fragments or obstruction. If either is present, continued observation or secondary intervention is dictated by the severity of symptoms and/or obstruction. In persistently symptomatic patients without hydronephrosis or residual fragments further management is left to the discretion of the practitioner based on suspicion of urinary pathology.

The role of IVP in the followup of patients with ureteral calculi who have been treated surgically is limited. However, IVP or diuretic renography may be used in lieu of CT with contrast in patients who underwent ureteroscopic intact stone removal and

have persistent symptoms or hydronephrosis on sonogram, or in whom additional or residual ureteral stones are not suspected but there is concern for obstruction.

Finally, the timing of followup imaging studies or need for secondary intervention is left to the discretion of the treating physician. Since the degree of hydronephrosis does not correlate predictably with the degree of obstruction, the level of concern of the practitioner must dictate the need for and timing of further functional studies or definitive secondary intervention.

RISKS AND RESOURCE USE ASSOCIATED WITH URETERAL IMAGING

The performance characteristics of imaging modalities used in the management of ureteral calculous disease are well documented.⁵ However, despite consensus that NCCT of the abdomen and pelvis provides the most sensitive and specific information about the size and location of ureteral calculi,^{44,45} the superb performance characteristics of

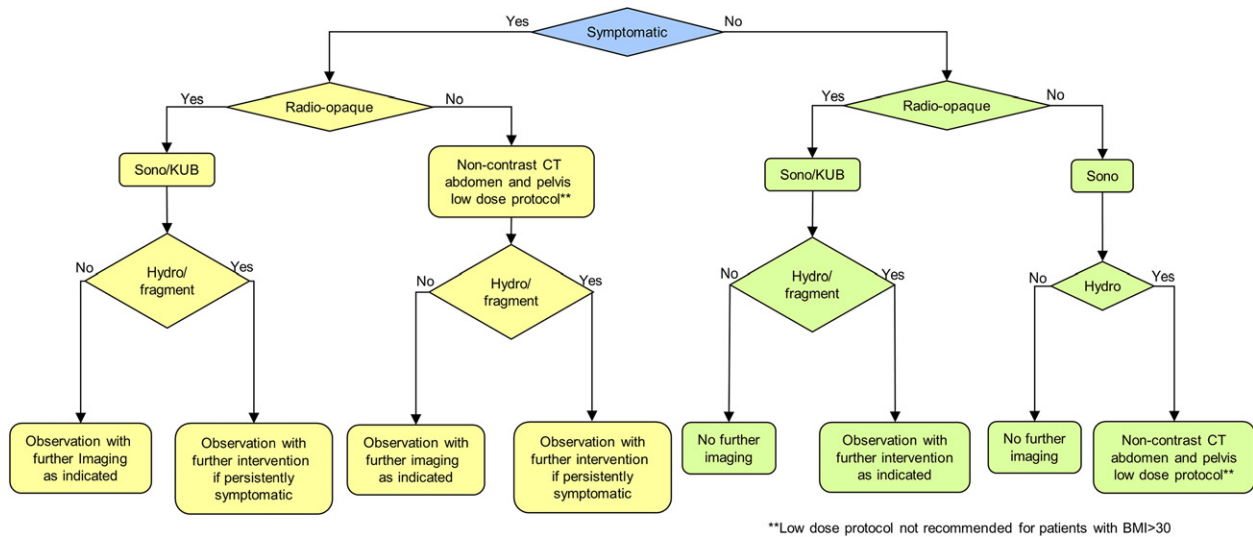


Figure 5. Followup after ureteroscopic extraction, requiring fragmentation (decision tree diagram 3C1)

CT must be balanced against its potential harms and costs.

RISKS ASSOCIATED WITH URETERAL IMAGING

All forms of conventional radiography and CT depend on ionizing radiation to create an image. Ionizing radiation is known to potentially cause harm through deterministic and stochastic effects. Deterministic effects (eg erythema of the skin and generation of cataracts) occur at a given threshold, and the effect is proportional to the dose. Stochastic effects (eg the induction of secondary cancers or hereditary defects) may occur at any dose. The probability that a stochastic effect will occur increases with the dose, but the severity of the effect is independent of the dose. Deterministic effects are rarely encountered with diagnostic radiation doses associated with the management of ureteral calculous disease.

It is useful to quantify the risk of radiation exposure to patients and health care providers using the concept of effective dose. Effective dose (in mSv) estimates the potential adverse biological effect of the sum of the equivalent doses of radiation to exposed organs. Therefore, radiation exposure from various types of diagnostic imaging studies can be compared in terms of relative biological risk. Effective dose cannot be equated to the actual absorbed dose for any individual. The actual absorbed dose for an individual will depend on the scanning protocol and the equipment used. There is compelling evidence of wide variability in the effective dose produced during the same kind of examination (eg CT of the abdomen and pelvis) within an imaging facility and between imaging facilities.⁴⁶ Actual doses

in clinical practice may be considerably higher due to several factors.⁴⁶

In addition to the harms associated with radiation exposure, imaging studies using IV contrast (iodine or gadolinium) have associated risks. Adverse reactions including severe allergic reactions, impaired renal function, nephrogenic systemic fibrosis and death have been reported.⁴⁷

MINIMIZING RISKS

All imaging studies using ionizing radiation should aspire to the ALARA principle (As Low As Reasonably Achievable),⁴⁸ attempting to expose the patient to the least ionizing radiation that will answer the clinical question at hand. Thus, when 2 or more imaging studies have equal or nearly equal clinical effectiveness, the study with the least ionizing radiation should be selected. A noncontrast study should be selected over one using contrast when its performance would be equally effective.

Optimization of selected studies should be pursued. For example, the sensitivity of abdominal ultrasound or KUB for the detection of a ureteral calculus may be optimized by withholding food and fluid before the examination to reduce the adverse effects of bowel gas on sensitivity and specificity.⁴⁹ Similarly, the optimization of conventional radiographs used to identify ureteral calculi may be accomplished by measures to decrease bowel gas, or by adding oblique images or tomograms to reduce missed detection from underlying or overlying structures.

Optimization of CT includes limited scanning protocols confined to an anatomical region of interest (eg pelvic CT) for evaluation of the distal ureter, adjustments of CT parameters for tissue thickness and body

habitus and limitation of phases (eg noncontrast only or combined injection and delayed phases) to reduce total radiation exposure. Specific protocols to reduce radiation exposure for the detection of ureteral calculous disease have been successful in decreasing the effective dose of a standard abdominal and pelvic CT from 10 to 3 mSv.⁵⁰

Specific scanning protocols for imaging facilities may vary significantly based on the wide range of estimates of effective dose found in the literature for a given examination. Clinicians will need to understand which scanning protocols are being used in imaging their patients.

RESOURCE USE

A study is justified when the benefits of the information obtained outweigh the potential physical and economic harms to the patient. Therefore, it is also reasonable to consider the cost of an imaging study to the individual patient and to the health care system. Health care resources are finite. Therefore, cost-effectiveness becomes the third factor (along with performance characteristics and risks) in considering the overall clinical effectiveness of an imaging study.

COSTS OF IMAGING

The costs of imaging vary widely and are dependent in part on market related factors and who is responsible for payment. One surrogate for relative cost is the maximum allowable charges assigned to the study by CMS (Centers for Medicare & Medicaid Services). Actual charges by imaging providers for each study may be considerably higher than the CMS allowed charge. By looking at relative charges, it is possible to have a sense of cost. For example, NCCT has charges that are twice as high as ultrasound, while magnetic resonance imaging charges are threefold higher than CT. However, it is important to keep in mind that charges are artificial and may not correspond proportionately to cost, which reflects the actual cost of the resources required to provide a given service. In fact, the allowable charge for CT has been aggressively cut by CMS in an attempt to limit use.

While medical decision making should not be compromised by cost, it is often possible to make rational medical decisions without additional imaging studies or with a lower cost option. In those cases in which the information may be obtained by 2 equally sensitive or nearly equally sensitive imaging modalities, the lower cost option should be favored. When a clinical question can be answered equally or nearly equally by 2 or more imaging modalities, the modality with the least harm and lowest overall resource use should be selected.

SUMMARY

This Technology Assessment has produced clinical effectiveness protocols which attempt to summarize information about the 1) performance characteristics, 2) risks and 3) costs of imaging studies to provide a rational approach to imaging in the management of ureteral calculous disease.

ACKNOWLEDGMENTS

James Robert White provided methodological expertise and made invaluable contributions to the evidence review and analysis. Angela Clark provided project management and support of the panel.

DISCLAIMER

This document was written by the Imaging Pilot Panel of the American Urological Association (AUA) Education and Research, Inc., which was created in 2011. The Practice Guidelines Committee of the AUA selected the panel chair. Panel members were selected by the chair. Membership of the panel included urologists with specific expertise in this area. The mission of the committee was to develop guidance that is analysis-based or consensus-based, depending on Panel processes and available data, for optimal clinical practices in the use of imaging for the management of ureteral calculus.

While this clinical effectiveness protocol does not necessarily establish the standard of care, AUA seeks to recommend and to encourage compliance by practitioners with current best practices related to the condition being treated. As medical knowledge expands and technology advances, the document will change. Today, this guidance represents not absolute mandates but provisional proposals for treatment under the specific conditions described. For all these reasons, this document does not preempt physician judgment in individual cases. Treating physicians must consider variations in resources, and patient tolerances, needs, and preferences. Conformance with any clinical effectiveness protocol does not guarantee a successful outcome.

Although clinical effectiveness protocols are intended to encourage best practices and potentially encompass available technologies with sufficient data as of close of the literature review, they are necessarily time-limited. Clinical effectiveness protocols cannot include evaluation of all data on emerging technologies or management, including those that are FDA approved, which may immediately come to represent

accepted clinical practices. For this reason, the AUA does not regard technologies or management which

are too new to be addressed by this document as necessarily experimental or investigational.

REFERENCES

- Cho JS, Fulgham PF, Clark AR et al: Follow-up imaging after urologic imaging studies: comparison of radiologists' recommendation and urologists' practice. *J Urol* 2010; **184**: 254.
- Lotan Y, Cadeddu JA, Roerhborn CG et al: Cost-effectiveness of medical management strategies for nephrolithiasis. *J Urol* 2004; **172**: 2275.
- Medicare Payment Advisory Commission: Report to the Congress: Improving Incentives in the Medicare Program. Share of Total Dollars Spent on Imaging (all modalities), 2005. 2009; **4**: 91. Available at http://medpac.gov/chapters/Jun09_Ch04.pdf. Accessed January 29, 2013.
- Preminger GM, Tiselius HG, Assimos DG et al: 2007 Guideline for the management of ureteral calculi. *J Urol* 2007; **178**: 2418.
- Coursey CA, Casalino DD, Remer EM et al: ACR Appropriateness Criteria® acute onset flank pain—suspicion of stone disease. American College of Radiology 2011. Available at <http://www.acr.org/~media/ACR/Documents/AppCriteria/Diagnostic/AcuteOnsetFlankPainSuspicionStoneDisease.pdf>. Accessed January 28, 2013.
- Hyams ES, Korley FK, Pham JC et al: Trends in imaging use during the emergency department evaluation of flank pain. *J Urol* 2011; **186**: 2270.
- Kim BS, Hwang IK, Choi YW et al: Low-dose and standard-dose unenhanced helical computed tomography for the assessment of acute renal colic: prospective comparative study. *Acta Radiol* 2005; **46**: 756.
- Liu W, Esler SJ, Kenny BJ et al: Low-dose nonenhanced helical CT of renal colic: assessment of ureteric stone detection and measurement of effective dose equivalent. *Radiology* 2000; **215**: 51.
- Tack D, Sourtzis S, Delpierre I et al: Low-dose unenhanced multidetector CT of patients with suspected renal colic. *AJR Am J Roentgenol* 2003; **180**: 305.
- Johnston R, Lin A, Du J et al: Comparison of kidney-ureter-bladder abdominal radiography and computed tomography scout films for identifying renal calculi. *BJU Int* 2009; **104**: 670.
- Ege G, Akman H, Kuzucu K et al: Can computed tomography scout radiography replace plain film in the evaluation of patients with acute urinary tract colic? *Acta Radiol* 2004; **45**: 469.
- Fielding JR, Silverman SG and Samuel S: Unenhanced helical CT of ureteral stones: a replacement for excretory urography in planning treatment. *AJR Am J Roentgenol* 1998; **171**: 1051.
- Delakas D, Karyotis I, Daskalopoulos G et al: Independent predictors of failure of shockwave lithotripsy for ureteral stones employing a second-generation lithotripter. *J Endourol* 2003; **17**: 201.
- Hong YK and Park DS: Ureteroscopic lithotripsy using Swiss Lithoclast for treatment of ureteral calculi: 12-years experience. *J Korean Med Sci* 2009; **24**: 690.
- Salem HK: A prospective randomized study comparing shock wave lithotripsy and semirigid ureteroscopy for the management of proximal ureteral calculi. *Urology* 2009; **74**: 1221.
- Seitz C, Tanovic E, Kikic Z et al: Impact of stone size, location, composition, impaction, and hydronephrosis on the efficacy of holmium:YAG-laser ureterolithotripsy. *Eur Urol* 2007; **52**: 1751.
- Shigeta M, Kasaoka Y, Yasumoto H et al: Fate of residual fragments after successful extracorporeal shock wave lithotripsy. *Int J Urol* 1999; **6**: 169.
- Turunc T, Kuzgunbay B, Gul U et al: Factors affecting the success of ureteroscopy in management of ureteral stone diseases in children. *J Endourol* 2010; **24**: 1273.
- Youssef RF, El-Nahas AR, El-Assmy AM et al: Shock wave lithotripsy versus semirigid ureteroscopy for proximal ureteral calculi (<20 mm): a comparative matched-pair study. *Urology* 2009; **73**: 1184.
- al Rasheed SA, al Mugeiren MM, al-Faquih SR et al: Ultrasound detection rate of childhood urolithiasis. *Ann Trop Paediatr* 1992; **12**: 317.
- Dalla PL, Stacul F, Bazzocchi M et al: Ultrasonography and plain film versus intravenous urography in ureteric colic. *Clin Radiol* 1993; **47**: 333.
- Gorelik U, Ulish Y and Yagil Y: The use of standard imaging techniques and their diagnostic value in the workup of renal colic in the setting of intractable flank pain. *Urology* 1996; **47**: 637.
- Mitterberger M, Pinggera GM, Maier E et al: Value of 3-dimensional transrectal/transvaginal sonography in diagnosis of distal ureteral calculi. *J Ultrasound Med* 2007; **26**: 19.
- Ripolles T, Agramunt M, Errando J et al: Suspected ureteral colic: plain film and sonography vs unenhanced helical CT. A prospective study in 66 patients. *Eur Radiol* 2004; **14**: 129.
- Shokeir AA, Shoma AM, Mosbah A et al: Non-contrast computed tomography in obstructive anuria: a prospective study. *Urology* 2002; **59**: 861.
- Shokeir AA, El-Diasty T, Eassa W et al: Diagnosis of ureteral obstruction in patients with compromised renal function: the role of noninvasive imaging modalities. *J Urol* 2004; **171**: 2303.
- Moş C, Holt G, Iuhasz S et al: The sensitivity of transabdominal ultrasound in the diagnosis of ureterolithiasis. *Med Ultrason* 2010; **12**: 188.
- Karmazyn B, Frush DP, Applegate KE et al: CT with a computer-simulated dose reduction technique for detection of pediatric nephroureterolithiasis: comparison of standard and reduced radiation doses. *AJR Am J Roentgenol* 2009; **192**: 143.
- Passerotti C, Chow JS, Silva A et al: Ultrasound versus computerized tomography for evaluating urolithiasis. *J Urol* 2009; **182**: 1829.
- Andreoiu M and MacMahon R: Renal colic in pregnancy: lithiasis or physiological hydronephrosis? *Urology* 2009; **74**: 757.
- Butler EL, Cox SM, Eberts EG et al: Symptomatic nephrolithiasis complicating pregnancy. *Obstet Gynecol* 2000; **96**: 753.
- Elgamasy A and Elsherif A: Use of Doppler ultrasonography and rigid ureteroscopy for managing symptomatic ureteric stones during pregnancy. *BJU Int* 2010; **106**: 262.
- Elwagdy S, Ghoneim S, Moussa S et al: Three-dimensional ultrasound (3D US) methods in the evaluation of calcular and non-calicular ureteric obstructive uropathy. *World J Urol* 2008; **26**: 263.
- Kochakarn W, Ratana-Olarn K, Viseshsindh V et al: Ureteral calculi during pregnancy: review of the management at Ramathibodi Hospital. *J Med Assoc Thai* 2002; **85**: 433.
- Parulkar BG, Hopkins TB, Wollin MR et al: Renal colic during pregnancy: a case for conservative treatment. *J Urol* 1998; **159**: 365.
- Shokeir AA, Mahran MR and Abdulmaaboud M: Renal colic in pregnant women: role of renal resistive index. *Urology* 2000; **55**: 344.
- White WM, Zite NB, Gash J et al: Low-dose computed tomography for the evaluation of flank pain in the pregnant population. *J Endourol* 2007; **21**: 1255.
- ACOG Committee on Obstetric Practice: ACOG Committee Opinion. Number 299, September 2004 (replaces No. 158, September 1995). Guidelines for diagnostic imaging during pregnancy. *Obstet Gynecol* 2004; **104**: 647.
- Miller OF and Kane CJ: Time to stone passage for observed ureteral calculi: a guide for patient education. *J Urol* 1999; **162**: 688.
- Weizer AZ, Auge BK, Silverstein AD et al: Routine postoperative imaging is important after ureteroscopic stone manipulation. *J Urol* 2002; **168**: 46.
- Bugg CE, El-Galley R, Kenney PJ et al: Follow-up functional radiographic studies are not mandatory for all patients after ureteroscopy. *Urology* 2002; **59**: 662.

42. Karadag MA, Tefekli A, Altunrende F et al: Is routine radiological surveillance mandatory after uncomplicated ureteroscopic stone removal? *J Endourol* 2008; **22**: 261.
43. Karod JW, Danella J and Mowad JJ: Routine radiologic surveillance for obstruction is not required in asymptomatic patients after ureteroscopy. *J Endourol* 1999; **13**: 433.
44. Fowler JC, Cutress ML, Abubacker Z et al: Clinical evaluation of ultra-low dose contrast-enhanced CT in patients presenting with acute ureteric colic. *Br J Med Surg Urol* 2011; **4**: 56.
45. Palmer JS, Donaher ER, O'Riordan MA et al: Diagnosis of pediatric urolithiasis: role of ultrasound and computerized tomography. *J Urol* 2005; **174**: 1413.
46. Smith-Bindman R, Lipson J, Marcus R et al: Radiation dose associated with common computed tomography examinations and the associated lifetime attributable risk of cancer. *Arch Intern Med* 2009; **169**: 2078.
47. Fulgham PF and Bishoff JT: Urinary tract imaging. In: *Campbell-Walsh Urology*, 10th ed. Edited by AJ Wein, LR Kavoussi, AC Novick et al. Philadelphia: Elsevier 2012; chapt 4.
48. Newman B and Callahan M: ALARA (as low as reasonably achievable) CT 2011—executive summary. *Pediatr Radiol*, suppl., 2011; **41**: S453.
49. Park SJ, Yi BH, Lee HK et al: Evaluation of patients with suspected ureteral calculi using sonography as an initial diagnostic tool: how can we improve diagnostic accuracy? *J Ultrasound Med* 2008; **27**: 1441.
50. Zilberman DE, Tsivian M, Lipkin ME et al: Low dose computerized tomography for detection of urolithiasis—its effectiveness in the setting of the urology clinic. *J Urol* 2011; **185**: 910.