

EAU Guidelines on Urological Trauma

N.D. Kitrey (Chair), N. Djakovic, F.E. Kuehhas,
N. Lumen, E. Serafetinidis, D.M. Sharma
Guidelines Associates: Y. Abu-Ghanem, A. Sujenthiran,

TABLE OF CONTENTS

PAGE

1.	INTRODUCTION	6
1.1	Aim and objectives	6
1.2	Panel composition	6
1.3	Available publications	6
1.4	Publication history	6
2.	METHODS	6
2.1	Evidence sources	6
2.2	Peer review	7
3.	EPIDEMIOLOGY & CLASSIFICATION	7
3.1	Definition and Epidemiology	7
3.1.1	Genito-Urinary Trauma	7
3.2	Classification of trauma	7
3.2.1	Initial evaluation and treatment	8
4.	UROGENITAL TRAUMA GUIDELINES	8
4.1	Renal Trauma	8
4.1.1	Epidemiology, aetiology and pathophysiology	8
4.1.1.1	Definition and impact of the disease	8
4.1.1.2	Mode of injury	8
4.1.1.2.1	Blunt renal injuries	8
4.1.1.2.2	Penetrating renal injuries	8
4.1.1.3	Classification systems	8
4.1.2	Diagnostic evaluation	9
4.1.2.1	Patient history and physical examination	9
4.1.2.1.1	Summary of evidence and recommendations for patient history and physical examination	9
4.1.2.2	Laboratory evaluation	9
4.1.2.2.1	Recommendations for laboratory evaluation	9
4.1.2.3	Imaging: criteria for radiographic assessment	9
4.1.2.3.1	Ultrasonography (US)	10
4.1.2.3.2	Computed tomography	10
4.1.2.3.3	Other imaging modalities	10
4.1.3	Disease management	11
4.1.3.1	Conservative management	11
4.1.3.1.1	Blunt renal injuries	11
4.1.3.1.2	Penetrating renal injuries	11
4.1.3.2	Surgical management	12
4.1.3.2.1	Indications for renal exploration	12
4.1.3.2.2	Operative findings and reconstruction	12
4.1.3.2.3	Summary of evidence and Recommendations for management of renal trauma	13
4.1.4	Follow-up	13
4.1.4.1	Complications	13
4.1.4.2	Recommendations for follow-up	14
4.1.5	Iatrogenic renal injuries	14
4.1.5.1	Introduction	14
4.1.5.2	Incidence and aetiology	14
4.1.5.3	Diagnosis	15
4.1.5.4	Management	15
4.1.5.5	Summary of evidence and recommendations for the management of iatrogenic renal injuries	16
4.1.6	Algorithms	17
4.2	Ureteral Trauma	18
4.2.1	Incidence	18
4.2.2	Epidemiology, aetiology, and pathophysiology	18
4.2.3	Diagnosis	19

	4.2.3.1	Clinical diagnosis	19
	4.2.3.2	Radiological diagnosis	19
	4.2.4	Prevention of iatrogenic trauma	20
	4.2.5	Management	20
	4.2.5.1	Proximal and mid-ureteral injury	20
	4.2.5.2	Distal ureteral injury	20
	4.2.5.3	Complete ureteral injury	20
	4.2.6	Summary of evidence and recommendations for the management of ureteral trauma	21
4.3		Bladder Trauma	21
	4.3.1	Classification	21
	4.3.2	Epidemiology, aetiology and pathophysiology	22
	4.3.2.1	Non-iatrogenic trauma	22
	4.3.2.2	Iatrogenic bladder trauma (IBT)	22
	4.3.3	Diagnostic evaluation	23
	4.3.3.1	General evaluation	23
	4.3.3.2	Supplemental evaluation	24
		4.3.3.2.1 Cystography	24
		4.3.3.2.2 Cystoscopy	24
		4.3.3.2.3 Ultrasound	24
	4.3.4	Prevention	24
	4.3.5	Disease management	24
	4.3.5.1	Conservative management	24
	4.3.5.2	Surgical management	24
		4.3.5.2.1 Blunt non-iatrogenic trauma	24
		4.3.5.2.2 Penetrating non-iatrogenic trauma	25
		4.3.5.2.3 Iatrogenic bladder trauma	25
		4.3.5.2.4 Intravesical foreign body	25
	4.3.6	Follow-up	25
	4.3.7	Summary of evidence and recommendations for bladder injury	26
4.4		Urethral Trauma	26
	4.4.1	Epidemiology, aetiology and pathophysiology	26
	4.4.1.1	Iatrogenic urethral trauma	26
		4.4.1.1.1 Transurethral catheterisation	26
		4.4.1.1.2 Transurethral surgery	26
		4.4.1.1.3 Surgical treatment for prostate cancer	27
		4.4.1.1.4 Radiotherapy for prostate cancer	27
		4.4.1.1.5 Major pelvic surgery and cystectomy	27
	4.4.1.2	Non-iatrogenic urethral injuries	27
		4.4.1.2.1 Anterior urethral injuries (in males)	27
		4.4.1.2.2 Posterior urethral injuries (in males)	28
	4.4.1.3	Urethral injuries in females	28
	4.4.2	Diagnosis in males and females	29
	4.4.2.1	Clinical signs	29
	4.4.2.2	Further diagnostic evaluation	29
		4.4.2.2.1 Retrograde urethrography	29
		4.4.2.2.2 Ultrasound, computed tomography and magnetic resonance imaging	29
		4.4.2.2.3 Cystoscopy	30
	4.4.2.3	Summary	30
	4.4.3	Disease Management	30
	4.4.3.1	Anterior urethral injuries	30
		4.4.3.1.1 Blunt anterior urethral injuries	30
		4.4.3.1.2 Penile fracture-related anterior urethral injuries	30
		4.4.3.1.3 Penetrating anterior urethral injuries	30
	4.4.3.2	Posterior urethral injuries	30
		4.4.3.2.1 Blunt posterior urethral injuries	30
		4.4.3.2.1.1 Immediate management	31
		4.4.3.2.1.1.1 Partial posterior urethral rupture	31
		4.4.3.2.1.1.2 Complete posterior urethral rupture	31

	4.4.3.2.1.1.2.1	Immediate re-alignment	31
	4.4.3.2.1.1.2.2	Immediate urethroplasty	32
	4.4.3.2.1.1.3	Delayed primary treatment	32
	4.4.3.2.1.1.3.1	Delayed primary re-alignment	32
	4.4.3.2.1.1.3.2	Delayed primary urethroplasty	32
	4.4.3.2.1.1.4	Deferred treatment	32
	4.4.3.2.1.1.4.1	Deferred urethroplasty	32
	4.4.3.2.1.1.4.2	Deferred endoscopic treatment	33
	4.4.3.2.2	Penetrating posterior urethral injuries	33
	4.4.3.2.2.1	Female urethral injuries	33
	4.4.3.2.2.1.1	Iatrogenic urethral injuries	33
	4.4.3.3	Treatment algorithms	34
4.4.4		Summary of evidence and recommendations for the management of urethral trauma	37
	4.4.4.1	Summary of evidence and recommendations for the management of iatrogenic urethral trauma	37
4.5		Genital Trauma	37
	4.5.1	Introduction and background	37
	4.5.2	General principles and pathophysiology	38
	4.5.2.1	Gunshot wounds	38
	4.5.2.2	Bites	38
	4.5.2.2.1	Animal bites	38
	4.5.2.2.2	Human bites	38
	4.5.2.3	Sexual activity	38
	4.5.2.3.1	Sexual intercourse	38
	4.5.2.3.2	Sexual assault	38
	4.5.3	Organ-specific genital trauma	38
	4.5.3.1	Penile trauma	38
	4.5.3.1.1	Blunt penile trauma	38
	4.5.3.1.1.1	Penile fracture	38
	4.5.3.2	Penetrating penile trauma	39
	4.5.3.3	Penile avulsion injuries and amputation	40
	4.5.4	Scrotal trauma	40
	4.5.4.1	Blunt scrotal trauma	40
	4.5.4.1.1	Testicular dislocation	40
	4.5.4.1.2	Haematocoele	40
	4.5.4.1.3	Testicular rupture	41
	4.5.4.2	Penetrating scrotal trauma	41
	4.5.5	Genital trauma in females	41
	4.5.5.1	Coital injury of the female genital tract	41
	4.5.5.2	Blunt vulvar injuries	41
	4.5.6	Summary of evidence and recommendations for the management of genital trauma	42
5.		POLYTRAUMA, DAMAGE CONTROL AND MASS CASUALTY EVENTS	42
	5.1	Introduction	42
	5.1.1	The development of major trauma centres	42
	5.1.1.1	Summary of evidence and recommendations for polytrauma management	42
	5.2	Damage control	43
	5.3	Management principles: polytrauma and associated urological injury	43
	5.3.1	Summary of evidence and recommendations for management principles of polytrauma and associated urological injury	43
	5.4	Urological injury management in polytrauma	43
	5.4.1	Renal injury	43
	5.4.1.1	Renal preservation	44
	5.4.1.2	Summary of evidence and recommendations for the management of renal injury	44
	5.4.2	Ureteral injury	44
	5.4.2.1	Recommendations for the management of ureteral injury	45

5.4.3	Bladder trauma	45
5.4.3.1	Recommendations for the management of bladder trauma and urethral injury	45
5.4.4	Urethral injury	45
5.4.5	External genital injury	45
5.5	Mass casualty events	45
5.5.1	Triage	46
5.5.2	Urological role in the mass casualty setting	46
6.	REFERENCES	46
7.	CONFLICT OF INTEREST	67
8.	CITATION INFORMATION	67

1. INTRODUCTION

1.1 Aim and objectives

The European Association of Urology (EAU) Guidelines Panel for Urological Trauma have prepared these guidelines in order to assist medical professionals in the management of urological trauma in adults. Paediatric trauma is addressed in the EAU Paediatric Urology Guidelines [1].

It must be emphasised that clinical guidelines present the best evidence available to the experts but following guideline recommendations will not necessarily result in the best outcome. Guidelines can never replace clinical expertise when making treatment decisions for individual patients, but rather help to focus decisions – also taking personal values and preferences/individual circumstances of patients into account. Guidelines are not mandates and do not purport to be a legal standard of care.

1.2 Panel composition

The EAU Urological Trauma Guidelines Panel consists of an international group of experts with particular expertise in urological trauma. All experts involved in the production of this document have submitted potential conflict of interest statements, which can be viewed on the EAU Website Uroweb: <http://uroweb.org/guideline/urological-trauma/?type=panel>.

1.3 Available publications

A quick reference document, the Pocket Guidelines, is available in print and as an app for iOS and Android devices. These are abridged versions which may require consultation together with the full text version. A number of translated versions, alongside several scientific publications in European Urology, the Associations scientific journal, are also available [2-5]. All documents can be viewed through the EAU website: <http://uroweb.org/guideline/urological-trauma/>.

1.4 Publication history

The Urological Trauma Guidelines were first published in 2003. Standard procedure for EAU Guidelines includes an annual assessment of newly published literature in the field to guide future updates. All sections of the 2018 Urological Trauma guidelines, with the exception of sections relating to imaging modalities, have been updated.

2. METHODS

2.1 Evidence sources

For the 2018 Urological Trauma Guidelines, new and relevant evidence has been identified, collated and appraised through a structured assessment of the literature. A broad and comprehensive literature search, covering all sections of the Urological Trauma Guidelines was performed. Databases searched included Medline, EMBASE, and the Cochrane Libraries, covering a time frame between May 31st 2016 and June 1st 2017. A total of 4,768 unique records were identified, retrieved and screened for relevance. A detailed search strategy is available online: <http://uroweb.org/guideline/urological-trauma/?type=appendices-publications>. The majority of identified publications were comprised of case reports and retrospective case series. The lack of high-powered randomised controlled trials (RCTs) makes it difficult to draw meaningful conclusions. The panel recognises this critical limitation.

For the 2018 edition of the EAU Guidelines the Guidelines Office have transitioned to a modified GRADE methodology across all 20 guidelines [6, 7]. For each recommendation within the guidelines there is an accompanying online strength rating form which addresses a number of key elements namely:

1. the overall quality of the evidence which exists for the recommendation, references used in this text are graded according to a classification system modified from the Oxford Centre for Evidence-Based Medicine Levels of Evidence [8];
2. the magnitude of the effect (individual or combined effects);
3. the certainty of the results (precision, consistency, heterogeneity and other statistical or study related factors);
4. the balance between desirable and undesirable outcomes;
5. the impact of patient values and preferences on the intervention;
6. the certainty of those patient values and preferences.

These key elements are the basis which panels use to define the strength rating of each recommendation. The strength of each recommendation is represented by the words 'strong' or 'weak' [9]. The strength of each recommendation is determined by the balance between desirable and undesirable consequences of alternative management strategies, the quality of the evidence (including certainty of estimates), and nature and variability of patient values and preferences. The strength rating forms will be posted online for consultation.

Additional information can be found in the general Methodology section of this print, and online at the EAU website; <http://www.uroweb.org/guideline/>. A list of associations endorsing the EAU Guidelines can also be viewed online at the above address.

2.2 Peer review

The Urological trauma Guidelines were peer reviewed prior to publication in 2015.

3. EPIDEMIOLOGY & CLASSIFICATION

3.1 Definition and Epidemiology

Trauma is defined as a physical injury or a wound to living tissue caused by an extrinsic agent. Trauma is the sixth leading cause of death worldwide, accounting for 10% of all mortalities. It accounts for approximately five million deaths each year and causes disability to millions more [10, 11].

About half of all deaths due to trauma are in people aged 15-45 years with trauma being the leading cause of death in this age group [12]. Death from injury is twice as common in males, especially in relation to motor vehicle accidents (MVAs) and interpersonal violence. Trauma is therefore a serious public health problem with significant social and economic costs.

Significant variation exists in the causes and the effects of traumatic injuries between geographical areas, and between low, middle, and high-income countries. It should be noted that alcohol and drug abuse increase the rate of traumatic injuries by precipitating interpersonal violence, child and sexual abuse, and MVAs [13].

3.1.1 Genito-Urinary Trauma

Genito-urinary trauma is seen in both sexes and in all age groups, but is more common in males. The kidney is the most commonly injured organ in the genito-urinary system and renal trauma is seen in up to 5% of all trauma cases [14, 15], and in 10% of all abdominal trauma cases [16]. In MVAs, renal trauma is seen after direct impact into the seatbelt or steering wheel (frontal crashes) or from body panel intrusion in side-impact crashes [17].

Ureteral trauma is relatively rare and mainly due to iatrogenic injuries or penetrating gunshot wounds, both in military and civilian settings [18].

Traumatic bladder injuries are usually due to blunt causes (MVAs) and associated with pelvic fracture [19], although they may also be a result of iatrogenic trauma.

The anterior urethra is most commonly injured by blunt or "fall-astride" trauma, whereas the posterior urethra is usually injured in pelvic fracture cases, the majority of which are seen in MVAs [20].

Genital trauma is much more common in males due to anatomical considerations, more frequent participation in physical sports, violent events and combat. Of all genito-urinary injuries, a third to two thirds involve the external genitalia [21].

3.2 Classification of trauma

Traumatic injuries are classified by the World Health Organization (WHO) into intentional (either interpersonal violence related, war-related or self-inflicted injuries), and unintentional injuries (mainly MVAs, falls, and other domestic accidents). Intentional trauma accounts for approximately half of the trauma-related deaths worldwide [11]. A specific type of unintentional injury is iatrogenic injury which is created during therapeutic or diagnostic procedures by healthcare personnel.

Traumatic insults are classified according to the basic mechanism of the injury into penetrating, when an object pierces the skin, and blunt injuries.

Penetrating trauma is further classified according to the velocity of the projectile into:

1. high-velocity projectiles (e.g. rifle bullets - 800-1,000 m/sec);
2. medium-velocity projectiles (e.g. handgun bullets - 200-300 m/sec);
3. low-velocity items (e.g. knife stab).

High-velocity weapons inflict greater damage because the bullets transmit large amounts of energy to the tissues. They form a temporary expansive cavitation that immediately collapses and creates shear forces and destruction in a much larger area than the projectile tract itself. Cavity formation disrupts tissue, ruptures blood vessels and nerves, and may fracture bones away from the path of the missile. In lower velocity injuries, the damage is usually confined to the projectile tract.

Blast injury is a complex cause of trauma as it commonly includes both blunt and penetrating trauma, and may also be accompanied by a burn injury.

Several classifications are used to describe the severity and the features of a traumatic injury. The most common is the American Association for the Surgery of Trauma (AAST) injury scoring scale, which is widely used in renal trauma http://www.aast.org/library/traumatools/injuryscoring_scales.aspx [22]. For the other urological organs, general practice is that injuries are described by their anatomical site and severity (partial/complete).

3.2.1 **Initial evaluation and treatment**

The initial emergency assessment of a trauma patient is beyond the focus of these guidelines, and is usually carried out by emergency medicine and trauma specialised personnel. The first priority is stabilisation of the patient and treatment of associated life-threatening injuries. The initial treatment should include securing the airway, controlling external bleeding and resuscitation of shock. In many cases, physical examination is carried out during stabilisation of the patient.

A direct history is obtained from conscious patients, while witnesses and emergency personnel can provide valuable information about unconscious or seriously injured patients. In penetrating injuries, important information includes the size of the weapon in stabbings, and the type and calibre of the weapon used in gunshot wounds. The medical history should be as detailed as possible, as pre-existing organ dysfunction can have a negative effect on trauma patient outcome [23, 24]. It is essential that all persons treating trauma patients are aware of the risk of hepatitis B and C infection. An infection rate of 38% was reported among males with penetrating wounds to the external genitalia [25]. In any penetrating trauma, tetanus vaccination should be considered according to the patient's vaccination history and the features of the wound itself [26].

4. UROGENITAL TRAUMA GUIDELINES

4.1 **Renal Trauma**

4.1.1 **Epidemiology, aetiology and pathophysiology**

4.1.1.1 *Definition and impact of the disease*

Renal trauma occurs in approximately 1-5% of all trauma cases [15, 27]. Renal injuries are associated with young age and male gender, the incidence is approximately 4.9 per 100,000 of the population [28]. Most injuries can be managed conservatively as advances in imaging and treatment strategies have decreased the need for surgical intervention and increased organ preservation [16, 29, 30].

4.1.1.2 *Mode of injury*

4.1.1.2.1 *Blunt renal injuries*

Blunt mechanisms include MVAs, falls, vehicle-associated pedestrian accidents and assault [31]. A direct blow to the flank or abdomen during sports activities is another cause. Sudden deceleration or a crush injury may result in contusion or laceration of the parenchyma or the renal hilum. In general, renal vascular injuries occur in less than 5% of blunt abdominal trauma, while isolated renal artery injury is very rare (0.05-0.08%) [16] and renal artery occlusion is associated with rapid deceleration injuries.

4.1.1.2.2 *Penetrating renal injuries*

Gunshot and stab wounds represent the most common causes of penetrating injuries and tend to be more severe and less predictable than blunt trauma. In urban settings, the percentage of penetrating injuries can be 20% or higher [32, 33]. Bullets have the potential for greater parenchymal destruction and are most often associated with multiple-organ injuries [34]. Penetrating injury produces direct tissue disruption of the parenchyma, vascular pedicles, or collecting system.

4.1.1.3 *Classification systems*

The most commonly used classification system is that of the AAST [22]. This validated system has clinical relevance and helps to predict the need for intervention [17, 35, 36]. It also predicts morbidity after blunt or penetrating injury and mortality after blunt injury [17].

4.1.2 **Diagnostic evaluation**

4.1.2.1 *Patient history and physical examination*

Vital signs should be recorded throughout the diagnostic evaluation. Possible indicators of major injury include a history of a rapid deceleration event (fall, high-speed MVAs) or a direct blow to the flank. In the early resuscitation phase, special consideration should be given to pre-existing renal disease [37]. In patients with a solitary kidney, the entire functioning renal unit may be endangered [38, 39]. Since pre-existing abnormality makes injury more likely following trauma, hydronephrosis due to ureteropelvic junction (UPJ) abnormality, calculi, cysts and tumours may complicate a minor injury [39].

Physical examination may reveal an obvious penetrating trauma from a stab wound to the lower thoracic back, flanks and upper abdomen, or bullet entry or exit wounds. In stab wounds, the extent of the entrance wound may not accurately reflect the depth of penetration.

Blunt trauma to the back, flank, lower thorax or upper abdomen may result in renal injury. Flank pain, ecchymoses, abrasions, fractured ribs, abdominal distension and/or a mass and tenderness, raise the suspicion of renal involvement.

4.1.2.1.1 Summary of evidence and recommendations for patient history and physical examination

Summary of evidence	LE
Blunt injuries account for most renal trauma; however, penetrating injuries tend to be more severe.	3
The most valuable tool for classification is the grading scale of the AAST.	3

Recommendations	Strength rating
Assess haemodynamic stability upon admission.	Strong
Record past renal surgery, and known pre-existing renal abnormalities (ureteropelvic junction obstruction, large cysts, lithiasis).	Strong

4.1.2.2 *Laboratory evaluation*

Urinalysis, haematocrit and baseline creatinine are the most important tests. Haematuria, either non-visible or visible is often seen, but is neither sensitive nor specific enough to differentiate between minor and major injuries [40].

Major injury, such as disruption of the UPJ, pedicle injuries, segmental arterial thrombosis and approximately 9% of patients with stab wounds and renal injury may occur without haematuria [41, 42]. Haematuria that is out of proportion to the history of trauma may suggest pre-existing pathology [43]. A urine dipstick is an acceptable, reliable and rapid test to evaluate haematuria, however, the rate of false-negative results ranges from 3-10% [44].

Serial haematocrit determination is part of the continuous evaluation. A decrease in haematocrit and the requirement for blood transfusions are indirect signs of the rate of blood loss, and along with the patient's response to resuscitation, are valuable in the decision-making process. However, until evaluation is complete, it will not be clear whether this is due to renal trauma and/or associated injuries. Baseline creatinine measurement reflects renal function prior to the injury. An increased creatinine level usually reflects pre-existing renal pathology.

4.1.2.2.1 Recommendation for laboratory evaluation

Recommendation	Strength rating
Test for haematuria in a patient with suspected renal injury.	Strong

4.1.2.3 *Imaging: criteria for radiographic assessment*

Decisions to image in suspected renal trauma are based on the mechanism of injury and clinical findings. The goals of imaging are to grade the renal injury, document pre-existing renal pathology, demonstrate presence of the contralateral kidney and identify injuries to other organs. Haemodynamic status will determine the initial imaging pathway with unstable patients potentially requiring immediate damage control laparotomy.

There is general agreement in the literature that renal imaging should be undertaken in blunt trauma if there is visible haematuria or non-visible haematuria and hypotension (systolic blood pressure < 90 mmHg) [31, 45-48]. Patients with non-visible haematuria and no shock after blunt trauma have a low likelihood of concealing significant injury. Other accepted indications for renal imaging in blunt trauma are rapid deceleration

injury, direct flank trauma, flank contusions, fracture of the lower ribs and fracture of the thoracolumbar spine, regardless of the presence or absence of haematuria [31, 45-48].

In patients with penetrating trauma, with the suspicion of renal injury, imaging is indicated regardless of haematuria [31, 45-48].

4.1.2.3.1 Ultrasonography (US)

In the setting of abdominal trauma, US is used widely to assess the presence of haemoperitoneum. However, US has a low sensitivity for solid abdominal organ injury [49-51] and the American College of Radiologists (ACR) Renal Trauma guidelines considers US usually not appropriate in renal trauma [46].

The use of contrast enhanced US (CEUS) increases the sensitivity of US to solid organ injury [52]. However, its usefulness in renal injury is limited because microbubbles are not excreted into the collecting system, therefore CEUS cannot reliably demonstrate injuries to the renal pelvis or ureter. It is a possible no-radiation alternative to computed tomography (CT) in the follow-up of renal trauma [53-55].

4.1.2.3.2 Computed tomography

Computed tomography is the imaging modality of choice in haemodynamically stable patients following blunt or penetrating trauma. Computed tomography is widely available, can quickly and accurately identify and grade renal injury [56], establish the presence of the contralateral kidney and demonstrate concurrent injuries to other organs. Integration of whole body CT into the initial management of polytrauma patients significantly increases the probability of survival [57]. Although the AAST system of grading renal injuries is primarily based on surgical findings, there is a good correlation with CT appearances [57, 58].

In the setting of isolated renal trauma, multiphase CT allows the most comprehensive assessment of the injured kidney and includes pre-contrast and post-contrast arterial, nephrographic and delayed (pyelographic) phase images. Pre-contrast images may help identify subcapsular haematomas obscured on post-contrast sequences [58]. Administration of intravenous iodinated contrast media is essential. Concerns regarding contrast media worsening outcomes via renal parenchymal toxicity are likely unwarranted, with low rates of contrast-induced nephropathy seen in trauma patients [59]. Arterial phase images allow assessment of vascular injury and presence of active extravasation of contrast. Nephrographic phase images optimally demonstrate parenchymal contusions and lacerations. Delayed phase imaging reliably identifies collecting system/ureteric injury [60]. In practice, trauma patients usually undergo standardised whole body imaging protocols and multiphase imaging of the renal tract will not be routinely performed. If there is suspicion that renal injuries have not been fully evaluated, repeat renal imaging should be considered.

4.1.2.3.3 Other imaging modalities

Intravenous pyelography (IVP)

Intravenous pyelography can be used to confirm function of the injured kidney and presence of the contralateral kidney when CT is not available [46].

Intraoperative pyelography

One-shot, intraoperative IVP remains a useful technique to confirm the presence of a functioning contralateral kidney in patients too unstable to undergo pre-operative imaging [61]. The technique consists of a bolus intravenous injection of 2 mL/kg of radiographic contrast followed by a single plain film taken after ten minutes.

Magnetic resonance imaging (MRI)

The diagnostic accuracy of MRI in renal trauma is similar to that of CT [62, 63], but the logistical challenges of moving a trauma patient to the MRI suite and the need for MRI-safe equipment make routine evaluation of trauma patients by this imaging modality impractical.

Radionuclide scans

Radionuclide scans do not play a role in the immediate evaluation of renal trauma patients.

Summary of evidence	LE
A CT scan with enhancement of intravenous contrast material and delayed images is the best method for the diagnosis and staging of renal injuries in haemodynamically stable patients.	3

Recommendations	Strength rating
Perform a contrast enhanced computed tomography (CT) scan in blunt trauma patients with; <ul style="list-style-type: none"> • visible haematuria; • non-visible haematuria with haemodynamic instability; • a history of rapid deceleration injury and/or significant associated injuries; • penetrating abdominal or lower thoracic injury. 	Strong
Perform CT delayed phase images in case of haemodynamic stability.	Strong

4.1.3 **Disease management**

4.1.3.1 *Conservative management*

4.1.3.1.1 Blunt renal injuries

Haemodynamic stability is the primary criterion for the management of all renal injuries. Non-operative management has become the treatment of choice for most renal injuries. In stable patients, this means supportive care with bed-rest and observation. Primary conservative management is associated with a lower rate of nephrectomies, without any increase in the immediate or long-term morbidity [64]. Hospitalisation or prolonged observation for evaluation of possible injury after a normal abdominal CT scan, when combined with clinical judgment, is unnecessary in most cases [65]. All grade 1 and 2 injuries, either due to blunt or penetrating trauma, can be managed non-operatively. For the treatment of grade 3 injuries, most studies support expectant treatment [66-68].

Most patients with grade 4 and 5 injuries present with major associated injuries, and consequently often undergo exploration and nephrectomy [69], although emerging data indicate that many of these patients can be managed safely with an expectant approach [70]. An initially conservative approach is feasible in stable patients with devitalised fragments [71], although these injuries are associated with an increased rate of complications and late surgery [72]. Patients diagnosed with urinary extravasation from solitary injuries can be managed without major intervention with a resolution rate of > 90% [70, 73]. Similarly, unilateral main arterial injuries are normally managed non-operatively in a haemodynamically stable patient with surgical repair reserved for bilateral artery injuries or injuries involving a solitary functional kidney. Conservative management is also advised in the treatment of unilateral complete blunt arterial thrombosis. However, blunt arterial thrombosis in multiple injury trauma patients is usually associated with severe injuries and attempts at repair are usually unsuccessful [74].

4.1.3.1.2 Penetrating renal injuries

Penetrating wounds have traditionally been approached surgically. A systematic approach based on clinical, laboratory and radiological evaluation minimises the incidence of negative exploration without increasing morbidity from a missed injury [75]. Selective non-operative management of abdominal stab wounds is generally accepted following complete staging in stable patients [68, 76]. If the site of penetration by the stab wound is posterior to the anterior axillary line, 88% of such injuries can be managed non-operatively [77]. Stab wounds producing major renal injuries (grade 3 or higher) are more unpredictable and are associated with a higher rate of delayed complications if treated expectantly [78].

Isolated grade 4 injuries represent a unique situation where treatment of the patient is based solely on the extent of the renal injury. Gunshot injuries should be explored only if they involve the hilum or are accompanied by signs of ongoing bleeding, ureteral injuries, or renal pelvis lacerations [79]. Minor low-velocity gunshot and stab wounds may be managed conservatively with an acceptably good outcome [80]. In contrast, tissue damage due to high-velocity gunshot injuries can be more extensive and nephrectomy may be required. Non-operative management of penetrating injuries in selected stable patients is associated with a successful outcome in approximately 50% of stab wounds and up to 40% of gunshot wounds [81-83].

4.1.3.1.3 Interventional radiology

Angioembolisation has a central role in the non-operative management of blunt renal trauma in haemodynamically stable patients [84-86]. Currently there are no validated criteria to identify patients who require angioembolisation and its use in renal trauma remains heterogeneous. Generally, accepted CT findings indicating angioembolisation are active extravasation of contrast, arteriovenous fistula and pseudoaneurysm [87]. The presence of both active extravasation of contrast and a large haematoma (> 25 mm depth) predict the need for angioembolisation with good accuracy [87, 88]. Angioembolisation has been utilised in the non-operative management of all grades of renal injury, however it is likely to be most beneficial in the setting of high grade renal trauma (AAST > 3) [84-86]. Non-operative management of high-grade renal trauma, where angioembolisation is included in the management algorithm, can be successful in up to 94.9% of grade 3, 89% of grade 4 and 52% of grade 5 injuries [84, 85]. Increasing grade of renal injury is associated with

increased risk of failed angioembolisation and need for repeat intervention [89]. Repeat embolisation prevents nephrectomy in 67% of patients, open surgery after failed embolisation usually results in nephrectomy [89, 90]. Despite concerns regarding parenchymal infarction and the use of iodinated contrast media, there is evidence to suggest angioembolisation does not affect the occurrence or course of acute kidney injury following renal trauma [91]. In severe polytrauma or high operative risk, the main artery may be embolised, either as a definitive treatment or to be followed by interval nephrectomy.

Available evidence regarding angioembolisation in penetrating renal trauma is sparse. One older study found angioembolisation is three times more likely to fail in penetrating trauma [75]. However, angioembolisation has been used successfully to treat AVF and pseudo-aneurysms in the non-operative management of penetrating renal trauma [92]. With studies reporting successful non-operative management of penetrating renal trauma, angioembolisation must be critically considered in this setting [92, 93].

4.1.3.2 *Surgical management*

4.1.3.2.1 Indications for renal exploration

The need for renal exploration can be predicted by considering the type of injury, transfusion requirements, blood urea nitrogen (BUN), creatinine and injury grade [94]. However, management of renal injury may also be influenced by the decision to explore or observe associated abdominal injuries [95]. Continuing haemodynamic instability and unresponsiveness to aggressive resuscitation due to renal haemorrhage is an indication for exploration, irrespective of the mode of injury [75, 96]. Other indications include an expanding or pulsatile peri-renal haematoma, identified at exploratory laparotomy, performed for associated injuries. Persistent extravasation or urinoma are usually managed successfully with endo-urological techniques. Inconclusive imaging and a pre-existing abnormality or an incidentally diagnosed tumour may require surgery even after minor renal injury [43].

Grade 5 vascular injuries are regarded as an absolute indication for exploration, but parenchymal grade 5 patients who are stable at presentation may be safely treated conservatively [97-100]. In these patients, intervention is predicted by the need for continued fluid and blood resuscitation, peri-renal haematoma size > 3.5 cm and the presence of intravascular contrast extravasation [101].

4.1.3.2.2 Operative findings and reconstruction

The overall exploration rate for blunt trauma is less than 10% [96], and may be even lower, as the conservative approach is increasingly adopted [102]. The goals of exploration following renal trauma are control of haemorrhage and renal salvage.

Most series suggest the transperitoneal approach for surgery [103, 104]. Access to the pedicle is obtained either through the posterior parietal peritoneum, which is incised over the aorta, just medial to the inferior mesenteric vein or by bluntly dissecting along the plane of the psoas muscle fascia, adjacent to the great vessels, and directly placing a vascular clamp on the hilum [105]. During abdominal exploration for gunshot wounds if there is no evidence of active retroperitoneal bleeding (stable haematoma), significant urinary extravasation, or hilar disruption then the retroperitoneum should not be opened [106]. Central or expanding haematomas indicate injuries of the renal pedicle, aorta, or vena cava and are potentially life-threatening [107].

In cases with unilateral arterial intimal disruption, repair can be delayed, especially in the presence of a normal contralateral kidney. However, prolonged warm ischaemia usually results in irreparable damage and renal loss. Entering the retroperitoneum and leaving the confined haematoma undisturbed within the perinephric fascia is recommended unless it is violated and cortical bleeding is noted; temporarily packing the fossa tightly with laparotomy pads can salvage the kidney [108]. Haemorrhage can occur while the patient is resuscitated, warmed, and awaits re-exploration, however, careful monitoring is sufficient. A brief period of controlled local urinary extravasation is unlikely to result in a significant adverse event or impact overall recovery. During the following 48 to 72 hours, CT scans can identify injuries and select patients for reconstruction or continued expectant management [109]. Ureteral stenting or nephrostomy diversion should be considered after delayed reconstruction due to the increased risk of post-operative urinary extravasation.

Feasibility of renal reconstruction should be judged during the operation. The overall rate of patients who undergo a nephrectomy during exploration is approximately 13%, usually in patients with penetrating injuries and higher rates of transfusion requirements, haemodynamic instability, and higher injury severity scores [110]. Other intra-abdominal injuries also slightly increase the need for nephrectomy [111]. Mortality is associated with overall severity of the injury and not often a consequence of the renal injury itself [112]. In gunshot injuries caused by a high-velocity bullet, reconstruction can be difficult and nephrectomy is often required [113]. Renorrhaphy is the most common reconstructive technique. Partial nephrectomy is required when non-viable tissue is detected. Watertight closure of the collecting system, if open, is desirable, although closing the parenchyma over the injured collecting system also has good results. If the capsule is

not preserved, an omental pedicle flap or peri-renal fat bolster may be used for coverage [114]. The use of haemostatic agents and sealants in reconstruction can be helpful [115]. In all cases, drainage of the ipsilateral retroperitoneum is recommended. Following blunt trauma, repair of vascular injuries (grade 5) is seldom, if ever, effective [116]. Repair should be attempted in patients with a solitary kidney or bilateral injuries [117], but not in the presence of a functioning contralateral kidney [30]. Nephrectomy for main artery injury has outcomes similar to those of vascular repair and does not worsen post-treatment renal function in the short-term.

4.1.3.2.3 Summary of evidence and Recommendations for management of renal trauma

Summary of evidence	LE
Haemodynamic stability is the primary criterion for selecting patients for non-operative management.	3
Angioembolisation is effective in patients with active bleeding from renal injury, without other indications for immediate abdominal operation.	3
Renal reconstruction should be attempted if haemorrhage is controlled and there is sufficient viable renal parenchyma.	3

Recommendations	Strength rating
Manage stable patients with blunt renal trauma conservatively with close monitoring of vital signs.	Strong
Manage isolated grade 1-3 stab and low-velocity gunshot wounds in stable patients, expectantly.	Strong
Use angioembolisation for active renal bleeding if there are no other indications for immediate laparotomy.	Strong
Proceed with renal exploration in the presence of: <ul style="list-style-type: none"> • persistent haemodynamic instability; • expanding or pulsatile peri-renal haematoma; • grade 5 vascular injury; • exploration for associated injuries. 	Strong
Attempt renal reconstruction if haemorrhage is controlled and there is sufficient viable renal parenchyma.	Weak

4.1.4 Follow-up

The risk of complications in patients who have been treated conservatively increases with injury grade. Repeat imaging two to four days after trauma minimises the risk of missed complications, especially in grade 3-5 blunt injuries [118]. The usefulness of frequent CT scanning after injury has never been satisfactorily proven. Computed tomography scans should always be performed on patients with fever, unexplained decreased haematocrit or significant flank pain. Repeat imaging can be safely omitted for patients with grade 1-4 injuries as long as they remain clinically well [119].

Nuclear scans are useful for documenting and tracking functional recovery following renal reconstruction [120]. Follow-up should involve physical examination, urinalysis, individualised radiological investigation, serial blood pressure measurement and serum determination of renal function [71]. A decline in renal function correlates directly with injury grade; this is independent of the mechanism of injury and the method of management [121, 122]. Follow-up examinations should continue until healing is documented and laboratory findings have stabilised, although checking for latent renovascular hypertension may need to continue for years [123]. In general, the literature is highly limited on the long-term consequences of renal tissue trauma.

4.1.4.1 Complications

Early complications, occurring less than one month after injury, include bleeding, infection, perinephric abscess, sepsis, urinary fistula, hypertension, urinary extravasation and urinoma. Delayed complications include bleeding, hydronephrosis, calculus formation, chronic pyelonephritis, hypertension, AVF, hydronephrosis and pseudo-aneurysms. Delayed retroperitoneal bleeding may be life-threatening and selective angiographic embolisation is the preferred treatment [124]. Perinephric abscess formation is best managed by percutaneous drainage, although open drainage may sometimes be required. Percutaneous management of complications may pose less risk of renal loss than re-operation, when infected tissues make reconstruction difficult [96].

Renal trauma is a rare cause of hypertension, and is mostly observed in young men. The frequency of post-traumatic hypertension is estimated to be less than 5% [125, 126]. Hypertension may occur acutely as

a result of external compression from peri-renal haematoma (Page kidney), or chronically due to compressive scar formation. Renin-mediated hypertension may occur as a long-term complication, aetiologies include renal artery thrombosis, segmental arterial thrombosis, renal artery stenosis (Goldblatt kidney), devitalised fragments and AVF. Arteriography is informative in cases of post-traumatic hypertension. Treatment is required if the hypertension persists and can include medical management, excision of the ischaemic parenchymal segment, vascular reconstruction, or total nephrectomy [127].

Urinary extravasation after reconstruction often subsides without intervention as long as ureteral obstruction and infection are not present. Ureteral retrograde stenting may improve drainage and allow healing [128]. Persistent urinary extravasation from an otherwise viable kidney after blunt trauma often responds to stent placement and/or percutaneous drainage [129]. Arteriovenous fistulae usually present with delayed onset of significant haematuria, most often after penetrating trauma. Percutaneous embolisation is often effective for symptomatic AVF, but larger ones may require surgery [130]. Post-procedural complications include infection, sepsis, urinary fistula, and renal infarction [131]. The development of pseudo-aneurysm is a rare complication following blunt trauma. In numerous case reports, transcatheter embolisation appears to be a reliable minimally invasive solution [132]. Acute renal colic from a retained missile has been reported, and should be managed endoscopically, if possible [133].

4.1.4.2 Recommendations for follow-up

Recommendations	Strength rating
Repeat imaging in case of fever, worsening flank pain, or falling haematocrit.	Strong
Follow-up approximately three months after major renal injury with: <ul style="list-style-type: none"> physical examination; urinalysis; individualised radiological investigation including nuclear scintigraphy; serial blood pressure measurements; renal function tests. 	Weak

4.1.5 Iatrogenic renal injuries

4.1.5.1 Introduction

Iatrogenic renal trauma is rare, but can lead to significant morbidity.

4.1.5.2 Incidence and aetiology

The commonest causes of iatrogenic renal injuries are listed in Table 4.1.2 [134].

Table 4.1.2: Incidence and aetiology of commonest iatrogenic renal trauma during various procedures

Procedure	Haemorrhage	AVF	Pseudo-aneurysm	Renal pelvis Injury	Aortocaliceal fistula	Foreign body
Nephrostomy	+		+	+		
Biopsy	+(0.5-1.5%)	+	+(0.9%)			
PCNL	+	+		+		
Laparoscopic surgery (oncology)	+					
Open surgery (oncology)	+		+(0.43%)			+
Transplantation	+	+	+		+	
Endopyelotomy	+			+		+
Endovascular procedure	+(1.6%)					

AVF = arteriovenous fistulae; PCNL = percutaneous nephrolithotomy.

Large haematomas after biopsy (0.5-1.5%) are caused by laceration or arterial damage [135]. Renal artery and intraparenchymal pseudo-aneurysms (0.9%) may be caused by percutaneous biopsy, nephrostomy, and partial nephrectomy (0.43%) [136]. In percutaneous nephrolithotomy (PCNL), haemorrhage is the most dangerous iatrogenic renal trauma, especially when punctures are too medial or directly entering the renal pelvis. Other injuries include AVF or a tear in the pelvicaliceal system.

Iatrogenic renal injuries associated with renal transplantation include AVF, intrarenal pseudo-

aneurysms, arterial dissection and arteriovenous fistulas. Pseudo-aneurysm is a rare complication of allograft biopsy. Although the overall complication rate following biopsy in transplanted kidneys is 9% (including haematoma, AVF, visible haematuria and infection), vascular complications requiring intervention account for 0.2-2.0% [137]. Predisposing factors include hypertension, renal medullary disease, central biopsies, and numerous needle passes [138]. Arteriovenous fistulae and pseudo-aneurysms can occur in 1-18% of allograft biopsies [135].

Extra-renal pseudo-aneurysms after transplantation procedures generally occur at the anastomosis, in association with local or haematogenous infection. Arterial dissection related to transplantation is rare and presents in the early post-operative period [139].

Iatrogenic renal trauma associated with endopyelotomy is classified as major (vascular injury), and minor (urinoma) [140]. Patients undergoing cryoablation for small masses via the percutaneous or the laparoscopic approach may have asymptomatic perinephric haematoma and self-limiting urine leakage.

Vascular injury is a rare complication (1.6%) of endovascular interventions in contrast to patients with surgical injuries. The renal vessels are vulnerable mainly during oncological procedures [141]. Renal foreign bodies and retained sponges or wires during open or endo-urological procedures, are uncommon.

4.1.5.3 *Diagnosis*

Haematuria is common after insertion of nephrostomies, but massive retroperitoneal haemorrhage is rare. Following percutaneous biopsy, AVF may occur with severe hypertension. A pseudo-aneurysm should be suspected if the patient presents with flank pain and decreasing haematocrit, even in the absence of haematuria.

During PCNL, acute bleeding may be caused by injury to the anterior or posterior segmental arteries, whilst late post-operative bleeding may be caused by interlobar and lower-pole arterial lesions, AVF and post-traumatic aneurysms [142]. Duplex US and CT angiography can be used to diagnose vascular injuries. A close watch on irrigation fluid input and output is required to ensure early recognition of fluid extravasation. Intra-operative evaluation of serum electrolytes, acid-base status, oxygenation, and monitoring of airway pressure are good indicators of this complication.

In arterial dissection related to transplantation, symptoms include anuria and a prolonged dependence on dialysis. Doppler US can demonstrate compromised arterial flow. Dissection can lead to thrombosis of the renal artery and/or vein.

After angioplasty and stent-graft placement in the renal artery, during which wire or catheters may enter the parenchyma and penetrate through the capsule, possible radiological findings include AVF, pseudo-aneurysm, arterial dissection and contrast extravasation. Common symptoms of pseudo-aneurysms are flank pain and visible haematuria within two or three weeks after surgery [143]. Transplant AVF and pseudo-aneurysms may be asymptomatic or may cause visible haematuria or hypovolemia due to shunting and the 'steal' phenomenon, renal insufficiency, hypertension, and high output cardiac failure.

Patients with extrarenal pseudo-aneurysms (post-transplantation) may present with infection/bleeding, swelling, pain and intermittent claudication. Doppler US findings for AVFs include high-velocity, low-resistance, spectral waveforms, with focal areas of disorganised colour flow outside the normal vascular borders, and possibly a dilated vein [144]. Pseudo-aneurysms appear on US as anechoic cysts, with intracystic flow on colour Doppler US.

Potential complications of retained sponges include abscess formation, fistula formation to the skin or intestinal tract, and sepsis. Retained sponges may look like pseudo-tumours or appear as solid masses. Magnetic resonance imaging clearly shows the characteristic features [145]. Absorbable haemostatic agents may also produce a foreign body giant cell reaction, but the imaging characteristics are not specific. Retained stents, wires, or fractured Acucise cutting wires may also present as foreign bodies and can serve as a nidus for stone formation [146].

4.1.5.4 *Management*

If a nephrostomy catheter appears to transfix the renal pelvis, significant arterial injury is possible. The misplaced catheter should be withdrawn and embolisation may rapidly arrest the haemorrhage. Computed tomography can also successfully guide repositioning of the catheter into the collecting system [147]. Small subcapsular haematomas after insertion of nephrostomies resolve spontaneously, whilst AVFs are best managed by embolisation. Arteriovenous fistulae and pseudo-aneurysms after biopsy are also managed by embolisation [148].

During PCNL, bleeding can be venous or arterial. In major venous trauma with haemorrhage, patients with concomitant renal insufficiency can be treated without open exploration or angiographic embolisation using a Council-tip balloon catheter [149]. In the case of profuse bleeding at the end of a PCNL, conservative management is usually effective. The patient should be placed in the supine position, clamping the nephrostomy catheter and forcing diuresis. Super-selective embolisation is required in less than 1% of

cases and has proved effective in more than 90% [150]. Short-term deleterious effects are more pronounced in patients with a solitary kidney, but long-term follow-up shows functional and morphological improvements [151]. Termination of PCNL if the renal pelvis is torn or ruptured is a safe choice. Management requires close monitoring, placement of an abdominal or retroperitoneal drain and supportive measures [152]. Most surgical venous injuries include partial lacerations that can be managed with various techniques, such as venorrhaphy, patch angioplasty with autologous vein, or an expanded polytetrafluoroethylene (ePTFE) graft [153]. If conservative measures fail in cases of pseudo-aneurysm and clinical symptoms or a relevant decrease in haemoglobin occurs, transarterial embolisation should be considered [154]. As the success rate is similar for initial and repeat interventions, a repeat intervention is justified when the clinical course allows this [89].

Traditionally, patients with post-operative haemorrhage following intra-abdominal laparoscopic surgery of the kidney require laparotomy. Pseudo-aneurysms and AVF are uncommon after minimally invasive partial nephrectomy, but can lead to significant morbidity. Temporary haemostasis occurs with coagulation and/or tamponade, but later degradation of the clot, connection with the extravascular space, and possible fistula formation within the collecting system may develop. Patients typically present with visible haematuria, even though they may also experience flank pain, dizziness and fever. Embolisation is the reference standard for both diagnosis and treatment in the acute setting, although CT can be used if the symptoms are not severe and/or the diagnosis is ambiguous. Reports have described good preservation of renal function after embolisation [155].

Endoluminal management after renal transplantation consists of stabilising the intimal flap with stent placement. Embolisation is the treatment of choice for a symptomatic transplant AVF or enlarging pseudo-aneurysm [156]. Super-selective embolisation with a coaxial catheter and metallic coils helps to limit the loss of normal functioning graft tissue [157]. Failure of embolisation is associated with a high nephrectomy rate. The long-term outcome depends on the course of the transplant and the amount of contrast medium used during the procedure.

Surgical treatment for AVF consists of partial or total nephrectomy or arterial ligation, which results in loss of part of the transplant or the entire transplant. To date, surgery has been the main approach in the treatment of renal vascular injuries. In patients with retroperitoneal haematoma, AVF, and haemorrhagic shock, interventional therapy is associated with a lower level of risk compared to surgery [158]. Renal arteriography followed by selective embolisation can confirm the injury. In injuries during angioplasty and stent-graft placement, transcatheter embolisation is the first choice of treatment [159]. The treatment for acute iatrogenic rupture of the main renal artery is balloon tamponade. If this fails, immediate availability of a stent graft is vital [160]. The true nature of lesions caused by foreign bodies is revealed after exploration.

4.1.5.5 *Summary of evidence and recommendations for the management of iatrogenic renal injuries*

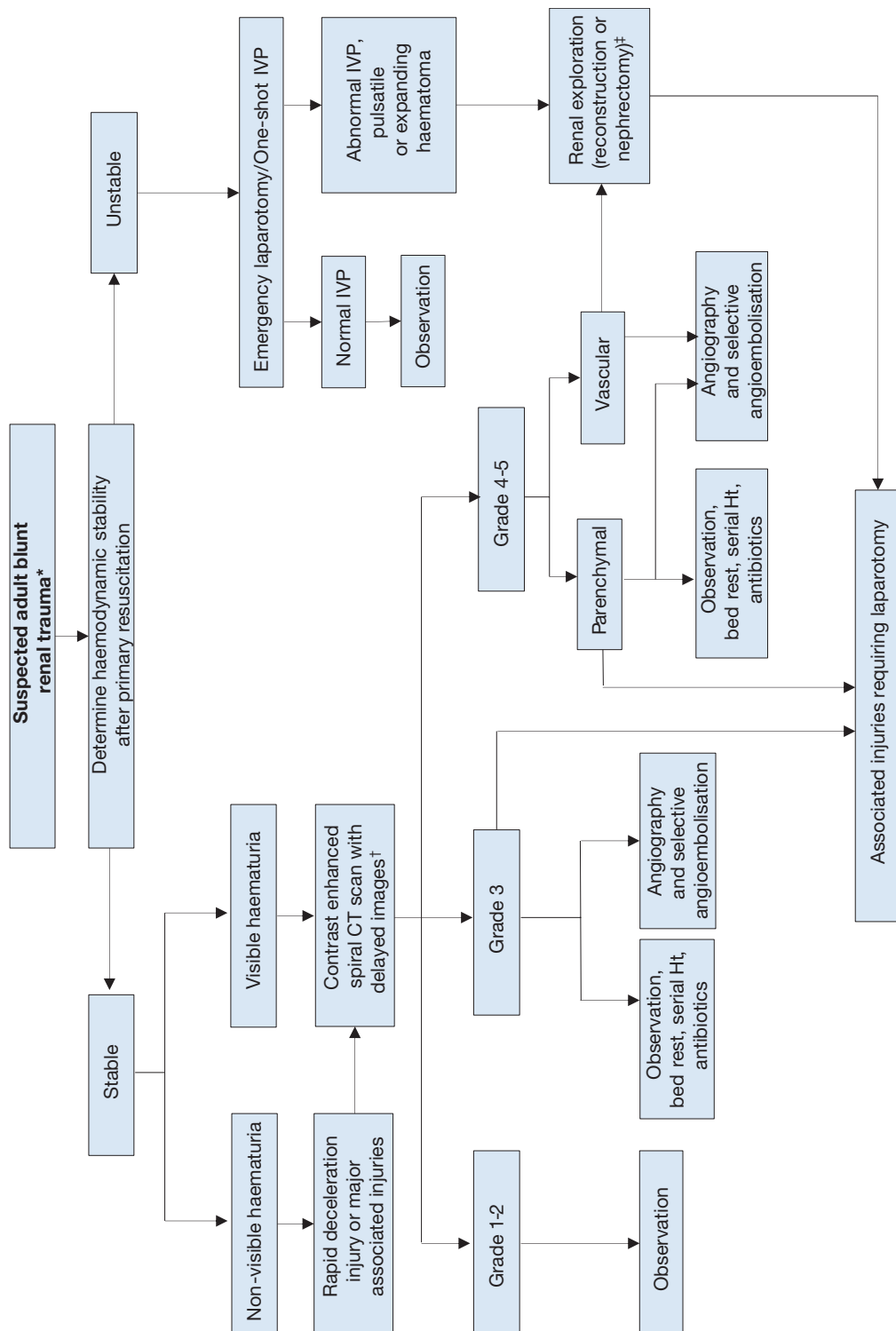
Summary of evidence	LE
Iatrogenic renal injuries are procedure-dependent (1.8-15%).	3
Significant injury requiring intervention is rare.	3
The most common injuries are vascular.	3
Renal allografts are more susceptible.	3
Injuries occurring during surgery are rectified immediately.	3
Symptoms suggestive of a significant injury require investigation.	3

The recommendations for iatrogenic renal injuries are the same as those for follow-up section 4.1.4.2.

4.1.6 Algorithms

Figures 4.1.1 and 4.1.2 show the suggested treatment for blunt and penetrating renal injuries in adults.

Figure 4.1.1 Evaluation of blunt renal trauma in adults



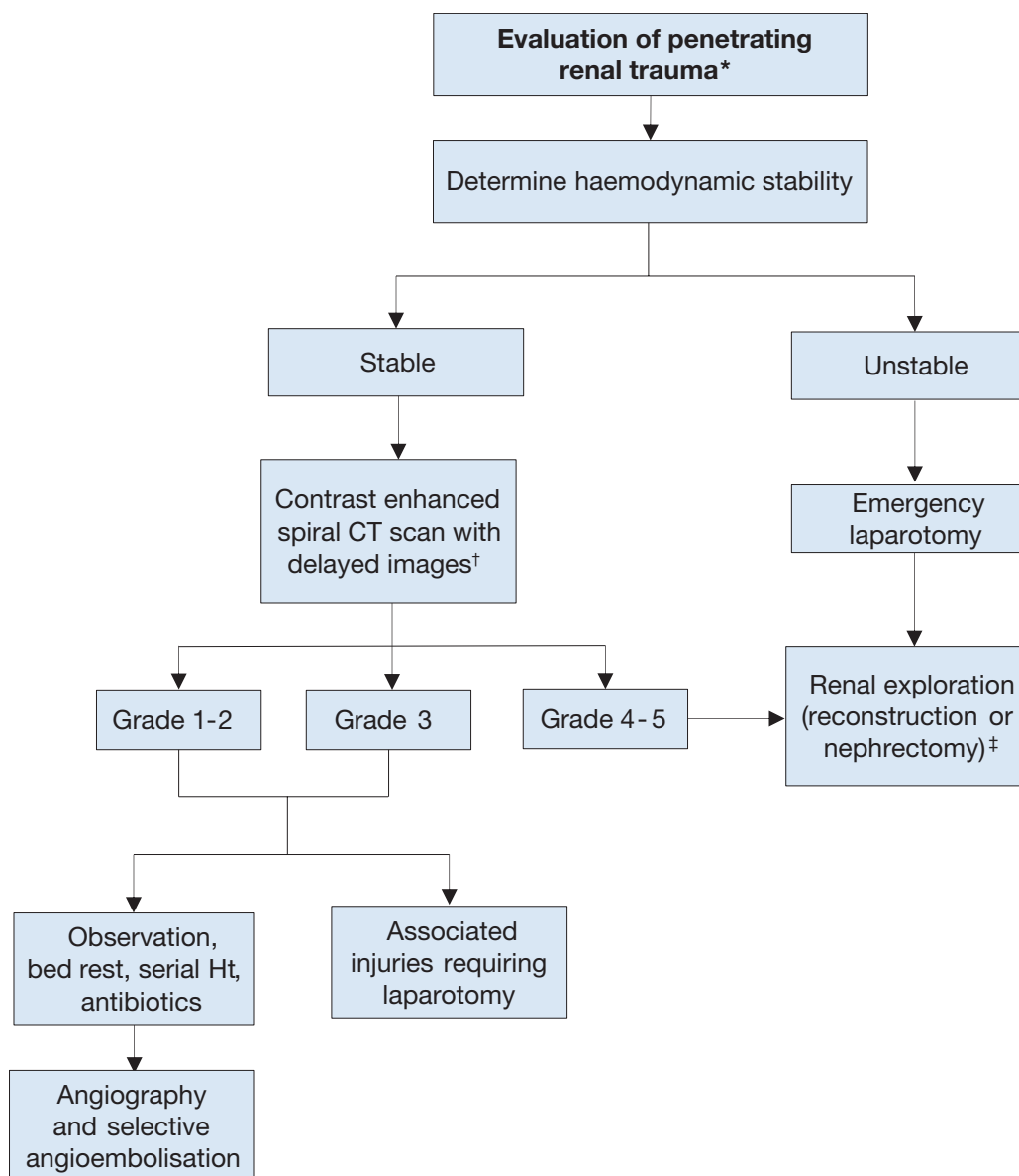
* Suspected renal trauma results from reported mechanism of injury and physical examination.

† Renal imaging: CT scans are the gold standard for evaluating blunt and penetrating renal injuries in stable patients. In settings where CT is not available, the urologist should rely on other imaging modalities (IVP, angiography, radiographic scintigraphy, MRI).

‡ Renal exploration: Although renal salvage is a primary goal for the urologist, decisions concerning the viability of the organ and the type of reconstruction are made during the operation.

CT = computed tomography; Ht = haematocrit; IVP = intravenous pyelography.

Figure 4.1.2 Evaluation of penetrating renal trauma in adults



* Suspected renal trauma results from reported mechanism of injury and physical examination.

† Renal imaging: CT scans are the gold standard for evaluating blunt and penetrating renal injuries in stable patients. In settings where CT is not available, the urologist should rely on other imaging modalities (IVP, angiography, radiographic scintigraphy, MRI).

‡ Renal exploration: Although renal salvage is a primary goal for the urologist, decisions concerning the viability of the organ and the type of reconstruction are made during the operation.

CT = computed tomography; Ht = haematocrit.

4.2 Ureteral Trauma

4.2.1 Incidence

Trauma to the ureters is relatively rare as they are protected from injury by their small size, mobility, and the adjacent vertebrae, bony pelvis and muscles. Iatrogenic trauma is the commonest cause of ureteral injury (approximately 80%) [161]. It is seen in open, laparoscopic or endoscopic surgery and is often missed intra-operatively. Any trauma to the ureter may result in severe sequelae.

4.2.2 Epidemiology, aetiology, and pathophysiology

Overall, ureteral trauma accounts for 1-2.5% of urinary tract trauma [18, 161-163], with even higher rates in modern combat injuries [164]. Penetrating external ureteral trauma, mainly caused by gunshot wounds, dominates most of the modern series, both civilian and military [18, 161, 165]. About one-third of cases of external trauma to the ureters are caused by blunt trauma, mostly road traffic injuries [162, 163].

Ureteral injury should be suspected in all cases of penetrating abdominal injury, especially gunshot wounds, as it occurs in 2-3% of cases [161]. It should also be suspected in blunt trauma with a deceleration mechanism, as the renal pelvis can be torn away from the ureter [161]. The distribution of external ureteral injuries along the ureter varies between series, but it is more common in the upper ureter [18, 162, 163].

Iatrogenic ureteral trauma can result from various mechanisms: ligation or kinking with a suture, crushing from a clamp, partial or complete transection, thermal injury, or ischaemia from devascularisation [165-167]. It usually involves damage to the lower ureter [161, 165, 166, 168]. Gynaecological operations are the commonest cause of iatrogenic trauma to the ureters (Table 4.2.1), but it may also occur in colorectal operations, especially abdominoperineal resection and low anterior resection [169]. The incidence of urological iatrogenic trauma has decreased in the last twenty years [165, 170] due to improvements in technique, instruments and surgical experience.

Risk factors for iatrogenic trauma include conditions that alter the normal anatomy, e.g. advanced malignancy, prior surgery or irradiation, diverticulitis, endometriosis, anatomical abnormalities, and major haemorrhage [165, 169, 171]. Occult ureteral injury occurs more often than reported and not all injuries are diagnosed intra-operatively. In gynaecological surgery, if routine intra-operative cystoscopy is used, the detection rate of ureteral trauma is five times higher than usually reported [171, 172].

Table 4.2.1: Incidence of ureteral injury in various procedures

Procedure	Percentage %
Gynaecological [168, 172, 173]	
Vaginal hysterectomy	0.02 – 0.5
Abdominal hysterectomy	0.03 – 2.0
Laparoscopic hysterectomy	0.2 – 6.0
Urogynaecological (anti-incontinence/prolapse)	1.7 – 3.0
Colorectal [167, 172, 174]	
	0.15 – 10
Ureteroscopy [170]	
Mucosal abrasion	0.3 – 4.1
Ureteral perforation	0.2 – 2.0
Intussusception/avulsion	0 – 0.3
Radical prostatectomy [175]	
Open retropubic	0.05 – 1.6
Robot-assisted	0.05 – 0.4

4.2.3 **Diagnosis**

The diagnosis of ureteral trauma is challenging, therefore, a high index of suspicion should be maintained. In penetrating external trauma, it is usually made intra-operatively during laparotomy [176], while it is delayed in most blunt trauma and iatrogenic cases [165, 168, 177].

4.2.3.1 *Clinical diagnosis*

External ureteral trauma usually accompanies severe abdominal and pelvic injuries. Penetrating trauma is usually associated with vascular and intestinal injuries, while blunt trauma is associated with damage to the pelvic bones and lumbosacral spine injuries [162, 163]. Haematuria is an unreliable and poor indicator of ureteral injury, as it is present in only 50-75% of patients [161, 165, 178].

Iatrogenic injury may be noticed during the primary procedure, when intravenous dye (e.g. indigo carmine) is injected to exclude ureteral injury. However, it is usually noticed later, when it is discovered by subsequent evidence of upper tract obstruction, urinary fistulae formation or sepsis. The following clinical signs are characteristic of delayed diagnosis flank pain, urinary incontinence, vaginal or drain urinary leakage, haematuria, fever, uraemia or urinoma. When the diagnosis is missed, the complication rate increases [161, 164, 177]. Early recognition facilitates immediate repair and provides better outcome [173, 179].

4.2.3.2 *Radiological diagnosis*

Extravasation of contrast medium on CT is the hallmark sign of ureteral trauma. However, hydronephrosis, ascites, urinoma or mild ureteral dilation are often the only signs. In unclear cases, a retrograde or antegrade urography is the optimum standard for confirmation [165]. Intravenous pyelography, especially one-shot IVP, is unreliable in diagnosis, as it is negative in up to 60% of patients [161, 165].

4.2.4 **Prevention of iatrogenic trauma**

The prevention of iatrogenic trauma to the ureters depends upon the visual identification of the ureters and careful intra-operative dissection in their proximity [165-167]. The use of prophylactic pre-operative ureteral stent insertion assists in visualisation and palpation and is often used in complicated cases (about 4% in a large cohort) [180]. It is probably also advantageous in making it easier to detect ureteral injury [166] however, it does not decrease the rate of injury [165]. Apart from its evident disadvantages (potential complications and cost), a stent may alter the location of the ureter and diminish its flexibility [166, 174]. Routine prophylactic stenting is generally not cost-effective [166]. Another form of secondary prevention is intra-operative cystoscopy after intravenous dye injection, which can provide confirmation of ureteral patency [168]. Routine cystoscopy has minimal risks and can markedly increase the rate of ureteral injury detection [172].

4.2.5 **Management**

Management of a ureteral trauma depends on many factors concerning the nature, severity and location of the injury. Immediate diagnosis of a ligation injury during an operation can be managed by de-ligation and stent placement. Partial injuries can be repaired immediately with a stent or urine diversion by a nephrostomy tube. Stenting is helpful because it provides canalisation and may decrease the risk of stricture [165]. On the other hand, its insertion has to be weighed against potentially aggravating the severity of the ureteral injury. Immediate repair of ureteral injury is usually advisable. However, in cases of unstable trauma patients, a 'damage control' approach is preferred with ligation of the ureter, diversion of the urine (e.g. by a nephrostomy), and a delayed definitive repair [181]. Injuries that are diagnosed late are usually treated first by a nephrostomy tube with or without a stent [165].

Endo-uological treatment of delayed-diagnosed ureteral injuries by internal stenting, with or without dilatation, is the first step in most cases. It is performed either retrogradely or antegradely through a PCN, and it has a variable success rate of 14 to 89% in published series [182-184]. An open surgical repair is necessary in case of failure. The basic principles for any surgical repair of a ureteral injury are outlined in Table 4.2.2. Wide debridement is highly recommended for gunshot wound injuries due to the 'blast effect' of the injury.

4.2.5.1 *Proximal and mid-ureteral injury*

Injuries shorter than 2-3 cm can usually be managed by a primary uretero-ureterostomy [161]. When this approach is not feasible, a uretero-calycostomy should be considered. In extensive ureteral loss, a transuretero-ureterostomy is a valid option, where the proximal stump of the ureter is transposed across the midline and anastomosed to the contralateral ureter. The reported stenosis rate is 4% and intervention or revision occur in 10% of cases [185].

4.2.5.2 *Distal ureteral injury*

Distal injuries are best managed by ureteral re-implantation (uretero-neocystostomy) because the primary trauma usually jeopardises the blood supply to the distal ureter. The question of refluxing vs. non-refluxing ureteral re-implantation remains unresolved in the literature. The risk for clinically significant reflux should be weighed against the risk for ureteral obstruction.

A psoas hitch between the bladder and the ipsilateral psoas tendon is usually needed to bridge the gap and to protect the anastomosis from tension. The contralateral superior vesical pedicle may be divided to improve bladder mobility. The reported success rate is very high (97%) [185]. In extensive mid-lower ureteral injury, the large gap can be bridged with a tubularised L-shaped bladder flap (Boari flap). It is a time-consuming operation and not usually suitable in the acute setting. The success rate is reported to be 81-88% [186].

4.2.5.3 *Complete ureteral injury*

A longer ureteral injury can be replaced using a segment of the intestines, usually the ileum (ileal interposition graft). This should be avoided in patients with impaired renal function or known intestinal disease. Follow-up should include serum chemistry to diagnose hyperchloremic metabolic acidosis [187]. The long-term complications include anastomotic stricture (3%) and fistulae (6%) [188]. In cases of extensive ureteral loss or after multiple attempts at ureteral repair, the kidney can be relocated to the pelvis (autotransplantation). The renal vessels are anastomosed to the iliac vessels and a ureteral re-implantation is performed [189].

Table 4.2.2: Principles of surgical repair of ureteral injury

Debridement of necrotic tissue.
Spatulation of ureteral ends.
Watertight mucosa-to-mucosa anastomosis with absorbable sutures.
Internal stenting.
External drain.
Isolation of injury with peritoneum or omentum.

Table 4.2.3: Reconstruction option by site of injury

Site of injury	Reconstruction options
Upper ureter	Uretero-ureterostomy
	Transuretero-ureterostomy
	Uretero-calycostomy
Mid ureter	Uretero-ureterostomy
	Transuretero-ureterostomy
	Ureteral re-implantation and a Boari flap
Lower ureter	Ureteral re-implantation
	Ureteral re-implantation with a psoas hitch
Complete	Ileal interposition graft
	Autotransplantation

4.2.6 Summary of evidence and recommendations for the management of ureteral trauma

Summary of evidence	LE
Iatrogenic ureteral trauma gives rise to the commonest cause of ureteral injury.	3
Gunshot wounds account for the majority of penetrating ureteral injuries, while MVAs account for most blunt injuries.	3
Ureteral trauma usually accompanies severe abdominal and pelvic injuries.	3
Haematuria is an unreliable and poor indicator of ureteral injury.	3
The diagnosis of ureteral trauma is often delayed.	2
Pre-operative prophylactic stents do not prevent ureteral injury, but may assist in its detection.	2
Endo-urological treatment of small ureteral fistulae and strictures is safe and effective.	3
Major ureteral injury requires ureteral reconstruction following temporary urinary diversion.	3

Recommendations	Strength rating
Visually identify the ureters to prevent ureteral trauma during abdominal and pelvic surgery.	Strong
Beware of concomitant ureteral injury in all abdominal penetrating trauma, and in deceleration-type blunt trauma.	Strong
Use pre-operative prophylactic stents in high-risk cases.	Strong

4.3 Bladder Trauma

4.3.1 Classification

The AAST proposes a classification of bladder trauma, based on the extent and location of the injury [190]. Practically the location of the bladder injury is important as it will guide further management (Table 4.3.1) [191]:

- intraperitoneal;
- extraperitoneal;
- combined intra-extraperitoneal.

Table 4.3.1: Classification of bladder trauma based on mode of action

Non-iatrogenic trauma
Blunt
Penetrating
Iatrogenic trauma
External
Internal
Foreign body

4.3.2 **Epidemiology, aetiology and pathophysiology**

4.3.2.1 *Non-iatrogenic trauma*

Motor vehicle traffic collisions are the most common cause of blunt bladder injury, followed by falls, industrial trauma/pelvic crush injuries and blows to the lower abdomen [162, 190, 192]. Between 60-90% of patients with bladder injuries caused by blunt trauma have associated pelvic fractures, and 44-68.5% of patients with bladder injuries have at least one other intra-abdominal injury [193, 194]. Pelvic fractures are associated with bladder injuries in only 3.6% of cases [162]. The incidence of extraperitoneal (22.4-61.1%), and intraperitoneal (38.9-65.8%) injuries varies among series [195]. A combination of bladder and urethral injury is present in 5-20% of cases [191, 194, 196].

Extraperitoneal ruptures are almost always associated with pelvic fractures [192, 194]. The injury is usually caused by distortion of the pelvic ring, with shearing of the anterolateral bladder wall near the bladder base (at its fascial attachments), or by a 'counter-coup' that bursts opposite the fracture site. Occasionally, the bladder is directly perforated by a sharp bony fragment [191]. The highest risk of bladder injury was found in disruptions of the pelvic circle with displacement > 1 cm, diastasis of the pubic symphysis > 1 cm and pubic rami fractures [162, 191]. An isolated acetabular fracture is not likely to be associated with bladder injury [191, 194].

Intraperitoneal ruptures are caused by a sudden rise in intravesical pressure of a distended bladder, secondary to a blow to the pelvis or lower abdomen. The bladder dome is the weakest point of the bladder and ruptures will usually occur there [191]. Penetrating injuries, mainly gunshot wounds, are rare except in conflict regions and some urban settings [190, 197, 198]. Improvised explosive devices are at present the main cause of combat related bladder injuries in asymmetric warfare [199].

4.3.2.2 *Iatrogenic bladder trauma (IBT)*

The bladder is the urological organ that most often suffers iatrogenic injury [200]. Table 4.3.2 shows the incidence of IBT during various procedures.

Table 4.3.2: Incidence of IBT during various procedures

Procedure	Percentage (%)
External	
Obstetrics	
Caesarean delivery [201]	0.08-0.94
Gynaecology	
Abdominal radical hysterectomy [202] (malignant)	2.37
Laparoscopic radical hysterectomy [202] (malignant)	4.19
Robotic radical hysterectomy [202] (malignant)	4.38-4.59
Laparoscopic hysterectomy [203] (benign)	1
Vaginal hysterectomy [203] (benign)	0.6
Abdominal hysterectomy [203] (benign)	0.9
General surgery	
Small/large bowel procedures [204]	0.12-0.14
Rectal procedures [204]	0.27-0.41
Abdominal cytoreductive surgery [205]	4.5
Laparoscopic inguinal hernia repair [206]	0.04-0.14
Urology	
Retropubic male sling [207]	8.0-50
Laparoscopic sacrocolpopexy [208]	1.9

Burch colposuspension [209, 210]	1.0-1.2
Mid-urethral sling (Transobturator route) [209]	1.61
Mid-urethral sling (Retropubic route) [209]	4.91
Pubovaginal sling [209]	2.8
Transvaginal mesh surgery [211]	2.84
Native tissue colporrhaphy [211]	0.53
Transurethral resection of the bladder [212, 213]	3.5-58

External IBT occurs most often during obstetric and gynaecological procedures, followed by general surgical and urological interventions [200]. Main risk factors are previous surgery, inflammation and malignancy [200].

Internal IBT mainly occurs during transurethral resection of the bladder (TURB). Reported risk factors are larger tumours, older age, pre-treated bladders (previous TURB, intravesical instillations) and location at the bladder dome [214, 215]. There is conflicting evidence whether bipolar TURB can reduce the risk of bladder perforation due to obturator jerk for tumours at the lateral wall [216, 217]. Perforations requiring intervention are rare (0.16-0.57%) [214]. Extraperitoneal perforations are more frequent than intraperitoneal perforations [215, 218].

Intravesical foreign bodies include:

- retained parts of endo-urologic equipment such as resectoscopes, ureteric stents or bladder catheters;
- forgotten pieces of surgical gauze, sutures or staples used in pelvic procedures;
- an unrecognised perforation or erosion of mesh used for correction of urinary incontinence or pelvic organ prolapse [219].

4.3.3 Diagnostic evaluation

4.3.3.1 General evaluation

The principal sign of bladder injury is visible haematuria [191, 192]. Non-iatrogenic bladder injury is strongly correlated with a combination of pelvic fracture and visible haematuria, and this combination is an absolute indication for further imaging [191]. Further imaging is also indicated in case of non-visible haematuria associated with either disruption of the pelvic circle with displacement > 1 cm or diastasis of the pubic symphysis > 1 cm and in case of posterior urethral injury [191]. In the absence of these absolute indications, the decision for further imaging should be based on the presence of other clinical signs and symptoms [191] which are summarised in Table 4.3.3.

Table 4.3.3: Clinical signs and symptoms of bladder injury

Signs and symptoms	Remarks
Haematuria [191, 192]	Visible = cardinal sign
Inability to void [191]	
Abdominal tenderness [191, 192]	
Abdominal distension [191]	In the case of urinary ascites
Uraemia and elevated creatinine level [191]	Intraperitoneal rupture => re-absorption of urea nitrogen and creatinine
Inadequate urinary output [191]	
Entrance/exit wounds at lower abdomen, perineum or buttocks [197, 220]	In penetrating injuries

Signs of external IBT are extravasation of urine, visible laceration, clear fluid in the surgical field, appearance of the bladder catheter, and blood and/or gas in the urine bag during laparoscopy [201]. Direct inspection is the most reliable method of assessing bladder integrity [200]. Intravesical instillation of methylene blue may be helpful to detect smaller lesions [221]. If bladder perforation is close to the trigone, the ureteric orifices should be inspected [200, 201].

Internal IBT is suggested by cystoscopic identification of fatty tissue, a dark space between detrusor muscle fibres, or the visualisation of bowel [212]. Signs of major perforation are the inability to distend the bladder, a low return of irrigation fluid, and abdominal distension [222].

Clinical signs and symptoms of an IBT not recognised during surgery include haematuria, abdominal pain, abdominal distension, ileus, peritonitis, sepsis, urine leakage from the wound, decreased urinary output, and increased serum creatinine [200, 201]. An IBT during hysterectomy or caesarean delivery can be complicated by respective vesico-vaginal or vesico-uterine fistula [201, 223].

Symptoms of an intravesical foreign body include dysuria, recurrent urinary tract infection,

frequency, urgency, haematuria, and perineal/pelvic pain [219, 224]. Bladder calculi may develop with chronic intravesical mesh exposure [219, 225].

4.3.3.2 *Supplemental evaluation*

4.3.3.2.1 *Cystography*

Cystography is the preferred diagnostic modality for non-iatrogenic bladder injury and for a suspected IBT in the post-operative setting [223, 226]. Both plain and CT cystography have a comparable sensitivity (90-95%) and specificity (100%) [192, 227]. However, CT cystography is superior in the identification of bony fragments in the bladder and bladder neck injuries as well as other abdominal injuries [191, 194].

Cystography must be performed using retrograde filling of the bladder with a minimum volume of 350 mL of dilute contrast material [226]. Passive bladder filling by clamping the urinary catheter during the excretory phase of CT or IVP is not sufficient to exclude bladder injury [192].

With intraperitoneal extravasation, free contrast medium is visualised in the abdomen, highlighting bowel loops and/or outlining abdominal viscera such as the liver [228]. Extraperitoneal bladder injury is associated with flame-shaped areas of contrast extravasation in the peri-vesical soft tissues. Contrast medium in the vagina is a sign of vesico-vaginal fistula [223].

4.3.3.2.2 *Cystoscopy*

Cystoscopy is the preferred method for detection of intra-operative bladder injuries, as it may directly visualise the laceration. Cystoscopy can localise the lesion in relation to the position of the trigone and ureteral orifices [228]. A lack of bladder distension during cystoscopy suggests a large perforation.

Cystoscopy is recommended to detect perforation of the bladder (or urethra) following suburethral sling operations by the retropubic route [210]. Routine intra-operative cystoscopy during benign gynaecologic procedures significantly increases the intra-operative detection rate, however, the post-operative detection rate remains unaffected [229]. Based on these findings, routine cystoscopy during benign gynaecologic procedures cannot be generally recommended, although the threshold to perform it should be low in case of suspicion of bladder injury. Cystoscopy is also preferred to diagnose a foreign body [219, 225].

4.3.3.2.3 *Ultrasound*

Demonstration of intraperitoneal fluid or an extraperitoneal collection suggests intraperitoneal or extraperitoneal perforation, respectively. However, US alone is insufficient in the diagnosis of bladder trauma.

4.3.4 **Prevention**

The risk of bladder injury is reduced by emptying the bladder by urethral catheterisation in every procedure where the bladder is at risk [221, 230]. Furthermore, the balloon of the catheter can aid in identification of the bladder [221]. For tumours at the lateral wall, obturator nerve block or general anesthesia with adequate muscle relaxation can reduce the incidence of internal IBT during TURB [217]. The use of combat pelvic protection systems reduces the risk of bladder and other genito-urinary injuries due to the blast mechanism of improvised explosive devices [199, 231].

4.3.5 **Disease management**

4.3.5.1 *Conservative management*

Conservative treatment comprises clinical observation, continuous bladder drainage and antibiotic prophylaxis [215]. This is the standard treatment for an uncomplicated extraperitoneal injury due to blunt trauma [191, 194, 196], after TURB or after other operations in which the injury was not recognised during surgery [215].

It is also an option for an uncomplicated intraperitoneal injury after TURB or after other operations in which the injury was not recognised during surgery, but only in the absence of peritonitis and ileus [213, 228]. In addition to conservative treatment, placement of an intraperitoneal drain is advocated, especially when the lesion is larger [222, 232].

On the rare occasion of a penetrating, minor and isolated extraperitoneal bladder injury, conservative management can be attempted [195, 220, 233].

4.3.5.2 *Surgical management*

Bladder closure is performed with absorbable sutures [195, 200]. There is no evidence of superiority of a two-layer vesicorrhaphy (mucosa-detrusor) compared to watertight single-layer closure [194, 195].

4.3.5.2.1 *Blunt non-iatrogenic trauma*

Although most extraperitoneal ruptures can be treated conservatively, bladder neck involvement, bone fragments in the bladder wall, concomitant rectal or vaginal injury or entrapment of the bladder wall will

necessitate surgical intervention [191]. There is an increasing trend to treat pelvic ring fractures with open stabilisation and internal fixation with osteosynthetic material. During this procedure, an extraperitoneal rupture should be sutured concomitantly in order to reduce the risk of infection [191, 192]. Similarly, during surgical exploration for other injuries, an extraperitoneal rupture should be sutured concomitantly in order to decrease the risk of complications and to reduce recovery time [196].

Intraperitoneal ruptures should always be managed by formal surgical repair [191, 194] because intraperitoneal urine extravasation can lead to peritonitis, intra-abdominal sepsis and death [193]. Abdominal organs should be inspected for possible associated injuries and urinomas must be drained if detected. In the absence of other intra-abdominal injuries, laparoscopic suturing of the intraperitoneal rupture is possible [192].

4.3.5.2.2 Penetrating non-iatrogenic trauma

The standard treatment is emergency exploration, debridement of devitalised bladder muscle and primary bladder repair [197, 198]. A midline exploratory cystotomy is advised to inspect the bladder wall and the distal ureters [195, 197]. In gunshot wounds, there is a strong association with intestinal and rectal injuries, requiring faecal diversion [197, 220]. Most gunshot wounds are associated with two transmural injuries (entry and exit wounds) and the bladder should be carefully checked for those two lesions [197]. As the penetrating agent (bullet, knife) is not sterile, concomitant antibiotic treatment is advised [198].

4.3.5.2.3 Iatrogenic bladder trauma

Perforations recognised intra-operatively are primarily closed [234].

For bladder injuries not recognised during surgery or for internal injuries, a distinction must be made between intraperitoneal and extraperitoneal injuries. For intraperitoneal injuries, the standard of care is surgical exploration with repair [228]. If surgical exploration is performed after TURB, the bowel must be inspected to rule out concomitant injury [214]. For extraperitoneal injuries, exploration is only needed for large perforations complicated by symptomatic extravescical collections. It requires drainage of the collection, with or without closure of the perforation [235].

If bladder perforation is encountered during mid-urethral sling or transvaginal mesh procedures, sling re-insertion and urethral catheterisation (two to seven days) should be performed [225].

4.3.5.2.4 Intravesical foreign body

For perforated or eroded meshes, the intravesical portion must be removed endoscopically or by open surgery (retropubic or transvaginal). It is advised to excise the mesh at least 1 cm beyond the bladder urothelium. As this can be better accomplished with open surgery, the risk of persistent or recurrent mesh exposure is lower when compared to endoscopic removal [219]. For other types of foreign bodies, cystoscopic removal is performed and if this fails cystotomy is needed [224, 236].

4.3.6 **Follow-up**

Continuous bladder drainage is required to prevent elevated intravesical pressure and to allow the bladder to heal [200, 237]. Conservatively treated bladder injuries (traumatic or external IBT) are followed by planned cystography scheduled to evaluate bladder healing, with catheter removal in case of absence of contrast extravasation [191]. The first cystography is planned approximately ten days after injury [195]. In case of ongoing leakage, cystoscopy must be performed to rule out bony fragments in the bladder and, if absent, cystography is done after one week [191].

After operative repair of a simple injury in a healthy patient, the catheter can be removed after seven to ten days without need for cystography [195, 237]. After repair of a complex injury (trigone involvement, ureteric reimplantation) or in the case of risk factors of wound healing (e.g. use of steroids, malnutrition), cystography is advised [195, 237].

For conservatively treated internal IBT, a catheter duration of five and seven days for extraperitoneal and intraperitoneal perforations, respectively, is proposed [215, 218].

4.3.7 **Summary of evidence and recommendations for bladder injury**

Summary of evidence	LE
The risk of bladder perforation during mid-urethral sling operations for stress urinary incontinence is lower for the obturator route compared to the retropubic route.	1a
The combination of pelvic fracture and visible haematuria is highly suggestive of bladder injury.	3

Recommendations	Strength rating
Perform cystography in case of suspected iatrogenic bladder injury in the post-operative setting.	Strong
Perform cystography in the presence of visible haematuria and pelvic fracture.	Strong
Perform cystography with active retrograde filling of the bladder with dilute contrast.	Strong
Use cystoscopy to rule out bladder injury after suburethral sling procedure by the retropubic route.	Strong
Manage a blunt extraperitoneal bladder injury operatively in cases of bladder neck involvement and/or associated injuries that require surgical Intervention.	Strong
Manage uncomplicated blunt extraperitoneal bladder injury conservatively.	Weak
Manage intraperitoneal injuries caused by blunt trauma by surgical exploration and repair.	Strong
Manage small uncomplicated iatrogenic intraperitoneal bladder injuries conservatively.	Weak
Do not perform cystography to assess bladder wall healing after repair of a simple injury in a healthy patient.	Weak
Perform cystography to assess bladder wall healing after repair of a complex injury or in case of risk factors for wound healing.	Strong

4.4 Urethral Trauma

4.4.1 *Epidemiology, aetiology and pathophysiology*

4.4.1.1 *Iatrogenic urethral trauma*

The most common type of urethral trauma seen in urological practice is iatrogenic, due to catheterisation, instrumentation or surgery [238, 239]. New treatment methods and applied energy sources can also injure the urethra [240].

4.4.1.1.1 Transurethral catheterisation

Iatrogenic urethral trauma usually results from improper or prolonged catheterisation and accounts for 32% of strictures [241]. Most of these strictures affect the bulbar urethra [240, 242], while the bladder neck is rarely affected in such cases [243].

The size and type of catheter used have an important impact on urethral stricture formation. Current data indicate that silicone catheters and small-calibre Foley catheters are associated with less urethral morbidity [244] (see Figure 4.4.3). Implementing training programmes may significantly decrease the incidence of such injuries, increase patient safety and reduce the negative long-term effects [239, 245].

4.4.1.1.2 Transurethral surgery

Transurethral procedures are a common cause of iatrogenic urethral trauma. Factors that may influence the development of iatrogenic endoscopic urethral strictures include electrical dispersion generated by uni- or bipolar current and the diameter of the instruments used [246]. The incidence of urethral strictures following mono- or bipolar transurethral resection of the prostate (TURP) appear to be equal, although some data indicates that bipolar TURP has a higher urethral stricture rate when used for higher prostate volumes (> 70 mL) [247] and that bladder neck strictures are also more common when bipolar TURP is used [248].

Predisposing factors most strongly associated with stricture formation in patients undergoing TURP are increased prostate volume, prostate cancer and the surgeon's experience [249]. Meatal strictures occur as a result of a mismatch between the size of the instrument and the diameter of the urethral meatus. Bulbar strictures occur due to insufficient insulation by the lubricant, causing the monopolar current to leak. To prevent strictures, lubricant gel should be applied carefully in the urethra. The lubricant must be re-applied when the resection time is prolonged [250]. Internal urethrotomy must be performed before TURP if there are pre-existing meatal or urethral strictures [250].

There appears to be no relationship with the duration of the procedure or the method used (holmium laser or traditional TURP) on the rate of stricture formation [251].

4.4.1.1.3 Surgical treatment for prostate cancer

Urethral stricture following prostate cancer treatment can occur anywhere from the bladder neck to the urethral meatus. The rate of bladder neck constriction after radical prostatectomy varies with the definition of the stricture used and individual practice [252, 253]. Published data shows that the incidence of urethral stricture after various forms of prostate cancer therapy is 1.1-8.4%. The risk is greatest after radical prostatectomy if combined with external-beam radiation therapy. In a multivariate analysis, primary treatment type, age and obesity were found to be significant predictors for stricture development [252, 254].

Robot-assisted prostatectomy also affects urinary function and the risk of iatrogenic trauma. Iatrogenic complications involving the bladder neck account for 2.2%, similar to the stricture rate found with

conventional treatment for localised prostate cancer [255].

Anastomotic stricture is a complication in conventional laparoscopic prostatectomy. If only prospective studies are taken into account, there is no significant difference in the anastomotic stricture rates comparing laparoscopic and robot-assisted radical prostatectomy [254, 256].

4.4.1.1.4 Radiotherapy for prostate cancer

The development of urinary fistulae has been reported after brachytherapy and radical prostatectomy, with incidences of 0.3-3.0% and 0-0.6%, respectively, with most fistulae involving the rectum [257, 258]. Brachytherapy is a recognised cause of strictures in patients with localised prostate cancer, as the CaPSURE study has shown [259]. Previous TURP increases the risk of stricture formation [260, 261].

4.4.1.1.5 Major pelvic surgery and cystectomy

Iatrogenic injuries to the urethra can be a complication of major pelvic procedures. Bladder and urethral catheterisation must therefore be carried out pre-operatively to prevent these complications [262]. Radical cystectomy and subsequent urinary diversion may also cause urethral trauma [263]. Table 4.4.1 lists the most common causes of urethral trauma.

Table 4.4.1: Most common causes of iatrogenic urethral trauma

Procedure	Percentage
Catheterisation	32% of iatrogenic urethral strictures (52% bulbar urethra)
Urethral instrumentation for therapy and/or diagnosis	
Treatment for prostatic disease	1.1-8.4% urethral stricture rate
Transurethral surgery (e.g. TURB/TURP)	2.2-9.8% urethral stricture rate
Radical prostatectomy (Radical prostatectomy and external-beam radiation)	0.5-32% bladder neck constriction; no difference between LRP and RALP (relative risk: 1.42; 95% confidence interval for relative risk, 0.40-5.06; p = 0.59)
Radiotherapy (percutaneous or brachytherapy)	6% urethral stricture rate, 0.3-3.0% urinary fistula rate
Radical prostatectomy and external-beam radiation therapy. This combination has the greatest risk for the formation of a urethral stricture	
Cryotherapy	
High-intensity focused ultrasound	
Treatment for bladder disease	
Cystectomy	3.1% subneovesical obstruction, 1.2% neovesicourethral anastomotic strictures, 0.9% urethral strictures
Injury during major abdominal and pelvic operations	

TURB = transurethral resection of the bladder; TURP = transurethral resection of the prostate; LRP = laparoscopic radical prostatectomy; RALP = robot-assisted laparoscopic radical prostatectomy.

4.4.1.2 Non-iatrogenic urethral injuries

4.4.1.2.1 Anterior urethral injuries (in males)

Different causes of anterior injuries [264] are listed in Table 4.4.2. Anterior urethral injuries are mainly caused by blunt trauma [264-266], with the bulbar urethra being the most common site injured [266, 267]. In these bulbar injuries, which are mostly 'straddle injuries' or kicks in the perineum, the bulb is compressed against the pubic symphysis, resulting in rupture of the urethra at this site [268].

Penetrating injuries of the penile or bulbar urethra are rare and usually caused by gunshot wounds [268-273]. Depending on the affected segment, penetrating injuries are usually associated with penile, testicular and/or pelvic injuries [270, 273].

Insertion of foreign bodies is another rare cause of anterior injury. It is usually a result of autoerotic stimulation or may be associated with psychiatric disorders [269]. Penile fractures account for 10-20% of anterior injuries [269]. In up to one-third of cases, the tear extends into the corpus spongiosum and urethra [274]. Urethral instrumentation is by far the most common cause of urethral trauma in the Western world and can affect all segments of the anterior urethra [275, 276].

Table 4.4.2: Aetiology of urethral injury

Cause	Example
Blunt trauma	Vehicular accidents
	Fall astride ('straddle') e.g. on bicycle, fences, inspection covers
	Kicks in the perineum
Sexual intercourse	Penile fractures
	Urethral intraluminal stimulation
Penetrating trauma	Gunshot wounds
	Stab wounds
	Dog bites
	External impalement
	Penile amputations
Constriction bands	Paraplegia
Iatrogenic injuries	Endoscopic instruments
	Urethral catheters/dilators

4.4.1.2.2 Posterior urethral injuries (in males)

Injuries to the posterior urethra are most often related to pelvic fractures (~72%) [275, 276], which themselves are usually caused by MVAs in up to 43% of cases [19, 238, 277, 278]. Iatrogenic posterior injuries, due to irradiation or surgery to the prostate, are an increasing problem [275, 276], but appear to be less common than previously believed (3-25%) [264].

Surgically, these injuries are divided into either partial or complete ruptures. In complete ruptures, there is a gap between the disrupted ends of the urethra. The dismembered ends of the urethra retract and fibrous tissue fills the space between them [238]. There is no urethral wall in the scarred space and any lumen represents merely a fistulous tract between the urethral stumps [238]. Injury to the posterior urethra exclusively occurs in pelvic fractures with disruption of the pelvic ring [19]. The highest risk of urethral injury is in straddle fractures with a concomitant diastasis of the sacroiliac joint, followed by straddle fractures alone, and Malgaigne fractures [279]. Displaced fractures of the inferomedial pubic bone and pubic symphysis diastasis, together with their degree of displacement, are independent predictors of urethral injury [277]. Injuries of the bladder neck and prostate are rare [280] and they mostly occur at the anterior midline of both the bladder neck and prostatic urethra. It is more rare to find a complete transection of the bladder neck or an avulsion of the anterior part of the prostate [280].

Penetrating injuries of the pelvis, perineum or buttocks (mainly gunshot wounds) can also cause damage to the posterior urethra, but are extremely rare [281]. There is a high probability of associated injuries (80-90%), mainly intra-abdominal [197, 281].

Although urethral injuries themselves are not directly life-threatening [19, 264], the association with pelvic fractures and concomitant injuries of the thorax, abdomen and spine, may be life-threatening [19, 277].

Delayed morbidity of posterior urethral injuries includes strictures, incontinence and erectile dysfunction (ED), which may all have a detrimental effect on the patient's quality of life [282]. Erectile dysfunction occurs in up to 45% of patients after traumatic posterior urethral rupture [282, 283]. Strong predictors for ED are diastasis of the pubic symphysis [282-285], lateral displacement of the prostate [282, 286], a long urethral gap (> 2 cm) [282], a bilateral pubic rami fracture and a Malgaigne's fracture [282]. The assessment of sexual function and the definitive treatment (e.g. penile prosthesis) should be performed two years after the trauma because of the potential return of potency within that time [282].

4.4.1.3 Urethral injuries in females

Urethral injuries are very rare in females [265, 268]. Pelvic fractures are the main aetiology [265]. The injury is usually a partial longitudinal tear of the anterior wall associated with vaginal laceration [265, 269]. Urethral injuries in females which extend into the bladder neck may disrupt the normal continence mechanism [287].

4.4.2 **Diagnosis in males and females**

4.4.2.1 *Clinical signs*

Blood at the meatus is the cardinal sign of urethral injury [238]. The absence of it, however, does not rule out a urethral injury.

An inability to void (with a palpable distended bladder) is another classic sign and is often associated with a complete rupture [238]. In addition, haematuria and pain on urination may be present. Interestingly, lower urinary tract pain is statistically more common in men < 40 years compared to men > 60 years [285]. Urinary extravasation and bleeding may result in scrotal, penile and/or perineal swelling and

ecchymosis, depending on the location and extent of the trauma [264, 269]. The presentation of these clinical symptoms may be delayed (> 1 hour) [238].

Rectal examination should always be done to exclude an associated rectal injury (up to 5% of cases) [191, 288] and may reveal a 'high-riding' prostate, which is an unreliable finding [191, 238]. Failure to detect a rectal injury can cause significant morbidity and even mortality [191]. A rectal injury is suggested by blood on the examining finger and/or a palpable laceration [191]. However, digital rectal examination may be deferred during the initial examination if the clinical situation does not permit it [289]. Another sign of urethral injury is difficulty or an inability to pass a urethral catheter [191].

A female urethral injury should be suspected from the combination of a pelvic fracture with blood at the vaginal introitus, vaginal laceration, haematuria, urethrorrhagia, labial swelling and/or urinary retention [265, 268, 269]. Vaginal examination is indicated to assess vaginal lacerations [191].

Symptoms of urethral lesions caused by improper catheterisation or instrumentation are penile and/or perineal pain (100%) and urethral bleeding (86%) [243]. Failure to accurately diagnose and treat urethral injuries may lead to significant long-term sequelae, mostly presenting as strictures [290, 291].

4.4.2.2 Further diagnostic evaluation

4.4.2.2.1 Retrograde urethrography

Retrograde urethrography is the standard diagnostic investigation for the acute evaluation of a male urethral injury [264]. A retrograde urethrography is conducted by injecting 20-30 mL of contrast material while occluding the meatus, with a balloon of a Foley catheter inflated in the fossa navicularis. Films should be taken in a 30°-oblique position, unless this is not possible because of the severity of the pelvic fractures and associated patient discomfort [264, 269]. In an unstable patient, retrograde urethrography should be postponed until the patient has been stabilised [197, 265].

A urethrogram allows for identification of the site of injury and assessment of the extent of any injury [191]. Any extravasation outside the urethra is pathognomonic for urethral injury. However, the distinction between a complete and partial rupture is not always clear [238]. A typical image for incomplete rupture shows extravasation from the urethra which occurs while the bladder is still filling. A complete rupture is suggested by massive extravasation without bladder filling [238].

The following classification of urethral injuries is based on retrograde urethrography (Table 4.4.3) [264]:

Table 4.4.3: Staging of urethral injuries*

Anterior urethra
Partial disruption
Complete disruption
Posterior urethra
Stretched but intact
Partial disruption
Complete disruption
Complex (involves bladder neck/rectum)

*According to the 2004 Consensus Panel on Urethral Trauma [264].

4.4.2.2.2 Ultrasound, computed tomography and magnetic resonance imaging

In the acute phase, US scanning is used for guiding the placement of a suprapubic catheter [264]. Computed tomography and rarely MRI are useful to evaluate concomitant injuries [264, 269].

4.4.2.2.3 Cystoscopy

Flexible cystoscopy is an option to diagnose (and manage) an acute urethral injury and may distinguish between complete- and incomplete rupture [264]. In addition, it may allow a guidewire to be passed into the bladder for early catheterisation [265, 292]. Flexible cystoscopy is also recommended above retrograde urethrography in suspected penile fracture-associated urethral injury [287, 293, 294]. In females, where the short urethra precludes adequate, radiological visualisation, urethroscopy and vaginoscopy are the diagnostic modalities of choice [264, 265]. Flexible urethroscopy also plays an important role during post-operative follow-up, as its routine use is associated with a higher detection rate of urethral stricture recurrence, compared to the use of urinary flow rates [295].

4.4.2.3 Summary

Prior to deferred management, the combination of retrograde urethrography and antegrade cysto-urethrography is standard [264]. The location and extent of the obliteration is diagnosed [264]. An MRI of the pelvis provides valuable additional information, which can help to determine the most appropriate surgical strategy [264, 286]. If the competence of the bladder neck is not clear upon antegrade cysto-urethrography, a suprapubic cystoscopy is advised [264].

Post-operative follow-up protocols include the use of retrograde urethrograms and voiding cysto-urethrography at the time of catheter removal. Following this, urine flow charts as well as post-void residual urine, cystoscopy and urine culture, should be performed at variable intervals.

4.4.3 Disease Management

4.4.3.1 Anterior urethral injuries

Anterior urethral injuries are usually not associated with other life-threatening injuries [269, 296]. Treatment decisions are based mainly on the type of injury (blunt, penile fracture associated or penetrating).

4.4.3.1.1 Blunt anterior urethral injuries

Blunt anterior urethral injuries are associated with spongiosal contusion, which makes it more difficult to evaluate the limits of urethral debridement in the acute phase. Acute or early urethroplasty is therefore not indicated [264]. The therapeutic options are suprapubic diversion or (a trial of) early endoscopic re-alignment with transurethral catheterisation [296]. Urinary diversion is maintained for two and three weeks for partial and complete ruptures, respectively [267].

Satisfactory urethral luminal re-canalisation may occur in up to 68% after partial ruptures, but is rare after complete ruptures [267, 297].

4.4.3.1.2 Penile fracture-related anterior urethral injuries

In order to preserve erectile function, penile fractures require early exploration [268, 287, 298, 299]. The strategy consists of closing the tear in the cavernosal tunica albuginea, while the concomitant tear in the urethra is repaired at the same time [298]. In these circumstances, there is no substantial urethral tissue loss [300]. A small laceration can be repaired by simple closure, while a complete rupture requires an anastomotic repair [298, 299].

4.4.3.1.3 Penetrating anterior urethral injuries

Immediate exploration is advised, except when this is precluded by other life-threatening injuries [264]. Devitalised tissues should be debrided, although urethral and spongiosal debridement should be kept to a minimum due to the excellent vascularisation [273, 287]. For small lacerations and stab wounds, simple urethral closure might be sufficient [264]. Defects of up to 2-3 cm in length in the bulbar urethra, and up to 1.5 cm in the penile urethra, can be treated by spatulation of the urethral ends and primary anastomosis [265, 271, 273]. In the case of longer defects or apparent infection (particularly bite wounds), a staged repair with urethral marsupialisation and a suprapubic catheter is needed [271, 273]. Peri- and post-operative antibiotic treatment is also necessary [272].

4.4.3.2 Posterior urethral injuries

4.4.3.2.1 Blunt posterior urethral injuries

In posterior injuries, it is important to distinguish between complete and partial ruptures prior to treatment. The timing of the surgical intervention is classified as [264, 265]:

- immediate: < 48 hours after injury (4.4.3.2.1.1);
- delayed primary: two days to two weeks after injury (4.4.3.2.1.2);
- deferred: > three months after injury (4.4.3.2.1.3).

4.4.3.2.1.1 Immediate management

Although urinary diversion is not essential during the first hours after trauma, many prefer to perform an early urinary diversion for three main reasons [238, 265]:

- to monitor urinary output, since this is a valuable sign of the haemodynamic condition and the renal function of the patient;
- to treat symptomatic retention if the patient is still conscious;
- to minimise urinary extravasation and its secondary effects, such as infection and fibrosis.

Insertion of a suprapubic catheter is always a good solution in urgent situations [264, 287]. However, insertion of a suprapubic catheter is not without risk, especially in the unstable trauma patient where the bladder is often displaced by the pelvic haematoma or because of poor bladder filling due to haemodynamic shock or

concomitant bladder injury. In these circumstances, an attempt at urethral catheterisation can be carried out by experienced hands. It is extremely unlikely that the gentle passage of a urethral catheter will do any additional damage [238, 265, 269, 275, 276, 300]. If there is any difficulty, a suprapubic catheter should be placed under US guidance and direct vision [238].

4.4.3.2.1.1.1 Partial posterior urethral rupture

Partial tears of the posterior urethra can be managed with a suprapubic or urethral catheter [287].

Urethrography should be performed at two-weekly intervals until healing has occurred [288, 301]. Injuries may heal without significant scarring or obstruction if managed by diversion alone [287]. A residual or subsequent stricture should be managed with:

- internal urethrotomy if it is short and non-obliterative;
- anastomotic urethroplasty, if it is long and dense, as is found with complete obliteration or after failed internal urethrotomy [297, 302].

4.4.3.2.1.1.2 Complete posterior urethral rupture

Acute definitive treatment options include:

- immediate re-alignment: apposition of the urethral ends over a catheter (4.4.3.2.1.1.2.1);
- immediate urethroplasty: suturing of urethral ends (4.4.3.2.1.1.2.2).

4.4.3.2.1.1.2.1 Immediate re-alignment

The aim of re-alignment is to correct severe distraction injuries rather than to prevent a stricture [287]. The reported benefits of re-alignment are:

- a lower stricture rate than with suprapubic catheter placement alone (where stricture formation is almost certain) [297, 302, 303];
- if scarring and subsequent stricture formation occurs, the restoration of urethral continuity is simplified;
- for short (< 2 cm), non-obliterative strictures, internal urethrotomy can be attempted, with a 50-90% success rate [297, 302, 304];
- for longer strictures, or in the case of failure of an internal urethrotomy, urethroplasty is required [302];
- if urethroplasty is required later, it is technically easier when the prostate and urethra are well aligned [300].

Endoscopic re-alignment is the preferred technique [265, 287]. Using a flexible/rigid cystoscope and biplanar fluoroscopy, a guidewire is placed inside the bladder. Over this, a catheter is placed into the bladder. If necessary, two cystoscopes can be used: one retrograde (per urethra) and one antegradely (suprapubic route through the bladder neck) [297, 302, 303]. The duration of catheter stay varies between four and eight weeks among series [191, 297, 302, 303].

It is important to avoid traction on the Foley balloon catheter since it can damage the remaining sphincter mechanism at the bladder neck. Concomitant bladder neck or rectal injuries or presence of bony fragments inside the bladder must be repaired immediately.

The reasons for immediate repair of bladder neck and rectal injury are:

- unrepaired bladder neck injury risks incontinence and infection of pelvic fractures;
- unrepaired rectal injury carries the obvious risk of sepsis and fistula, early exploration is indicated to evacuate contaminated haematomas and to perform colostomy if necessary.

Immediate endoscopic re-alignment can also be performed when the patient is on the operating table for other surgery. Early endoscopic re-alignment (immediate or delayed primary, see below) is also possible in a stable patient without significant concomitant injuries [302, 303].

With modern endoscopic re-alignment procedures, acceptable complication rates have been reported for stricture formation (14-79%), incontinence (< 5%) and impotence (10-55%) [302, 303].

Differences between series in the rates of incontinence, impotence and re-stricture can be explained by differences in patient selection (severe vs. less severe trauma), a mix of partial and complete ruptures, and differences in follow-up duration. Furthermore, these differences make the comparison with other techniques difficult, especially with urethroplasty [191, 297, 302, 303].

4.4.3.2.1.1.2.2 Immediate urethroplasty

Immediate urethroplasty with suturing of the urethral ends is difficult because of poor visualisation and the inability to assess accurately the degree of urethral disruption, due to extensive swelling and ecchymosis. This might lead to extensive unjustified urethral debridement [265]. Another problem is the risk of uncontrolled bleeding following entry into the pelvic haematoma, which may result in uncontrolled re-bleeding [265]. Due

to disturbingly high rates of impotence (56%), incontinence (21%) and strictures (69%) [301], immediate urethroplasty cannot be recommended and should only be done in experienced centres [306, 307].

4.4.3.2.1.1.3 Delayed primary treatment

Delayed treatment options include delayed primary re-alignment (4.4.3.2.1.2.1) and delayed primary urethroplasty (4.4.3.2.1.2.2).

4.4.3.2.1.1.3.1 Delayed primary re-alignment

In the absence of indications for immediate exploration, posterior urethral disruption can be managed in a delayed primary fashion. Delayed primary re-alignment requires the placement of a suprapubic tube at the time of initial injury, with endoscopic re-alignment performed within fourteen days (i.e. before fibrosis begins). At that time, patients are stable and most of the pelvic bleeding has resolved [301, 303]. The aim and proposed benefits of delayed primary re-alignment are the same as mentioned for immediate re-alignment. Endoscopic re-alignment is also the preferred modality.

4.4.3.2.1.1.3.2 Delayed primary urethroplasty

Delayed primary urethroplasty is performed no later than fourteen days after the initial injury i.e. before the start of the fibrotic process [308, 309]. If successful, it avoids a long period of suprapubic diversion [308]. It is restricted to stable patients with a short distraction defect, who are able to lie down in the lithotomy position [308]. Considering the limited accumulated experience with this approach, it cannot be generally recommended [308, 310, 311].

Supporters of early vs. delayed intervention state that it does not affect the outcome of an eventual subsequent urethroplasty [306, 312]. However, some authors have reported worse outcomes of subsequent urethroplasty after failed initial urethral manipulation (re-alignment or urethroplasty) [307, 308, 313]. Due to this concern and the excellent results obtained with deferred urethroplasty, early re-alignment or urethroplasty should only be selectively performed in highly experienced centres [306, 307].

4.4.3.2.1.1.4 Deferred treatment

In the case of a complete rupture, treated with an initial period of three months' suprapubic diversion, obliteration of the posterior urethra is almost inevitable [238, 301]. Treatment options for these posterior urethral strictures are deferred urethroplasty (4.4.3.2.1.3.1) and deferred endoscopic optical incision (4.4.3.2.1.3.2).

4.4.3.2.1.1.4.1 Deferred urethroplasty

Deferred urethroplasty is the procedure of choice for the treatment of posterior urethral distraction defects [287]. After three months of suprapubic diversion, the pelvic haematoma is nearly always resolved, the prostate has descended into a more normal position, the scar tissue has stabilised [308] and the patient is clinically stable and able to lie down in the lithotomy position [264, 265].

Most posterior urethral distraction defects are short and can be treated using a perineal anastomotic repair [264, 308]. The key objective of the operation is to achieve a tension-free anastomosis between two healthy urethral ends (i.e. after complete excision of any scar tissue) [287, 308].

After resection of fibrosis and spatulation of both healthy urethral ends, the gap between both ends is bridged by the so-called 'elaborated perineal approach', which is a series of consecutive manoeuvres, first described by Webster and Ramon [314] with reported success rates of 80-98% [315-319].

Most urethral stenoses are short and can be treated by mobilisation of the bulbar urethra, with or without separation of the corpora cavernosa [308]. This is in contrast to the situation in developing countries, where stenoses are more complex and where additional manoeuvres, such as inferior pubectomy and supracrural re-routing or a combined abdominoperineal approach, are needed more often [304, 316].

A number of situations may prevent the use of perineal anastomotic repair, either as an initial or as a salvage therapy. These situations probably represent < 5% of cases (Table 4.4.4) [320, 321].

Table 4.4.4: Circumstances that might preclude successful perineal anastomotic repair, either as an initial or as a salvage therapy [320, 321]

Circumstance	Alternative procedure
Distraction defects longer than 7-8 cm	A tubed interposition flap of penile or perineal skin can be used for reconstruction [322]. This is seldom required and most patients that require flap urethroplasties have previous failed repairs of posterior urethral rupture [287].
Fistulae	The interposition of tissue (e.g. the gracilis muscle, omentum, etc.) should be performed to support the closure of the fistula [316, 323].
Synchronous anterior urethral stricture	The presence of anterior urethral stricture may compromise the blood supply to the bulbar urethra following division of the bulbar arteries. These patients should be treated cautiously.
Urinary incontinence	The distal urethral sphincter mechanism can be defunctionalised by urethral distraction, so that urinary continence is maintained primarily by the proximal bladder neck sphincter. Concomitant bladder neck injury might increase incontinence and should require an abdominoperineal procedure to allow simultaneous bladder neck and urethral reconstruction [264, 287, 316].

Outcome after deferred urethroplasty is excellent with a stricture rate of around 10% [314, 324]. Deferred urethroplasty is unlikely to result in additional ED [308, 324]. Decompression of the erectile nerves after excision of the scar tissue might explain the amelioration of erectile function after urethroplasty [324]. Incontinence is rare with deferred urethroplasty (< 4%) [308] and is usually due to incompetence of the bladder neck [287, 316]. Standard therapy is deferred urethroplasty at a minimum of three months after trauma, using a one-stage perineal approach, whenever possible.

4.4.3.2.1.1.4.2 Deferred endoscopic treatment

Cold knife, laser core-through or cut-to-the light urethrotomy for complete urethral obliteration has been described. The results of this technique are poor [325, 326] and the procedure is therefore not recommended. For short, non-obliterative strictures following re-alignment or urethroplasty, direct vision urethrotomy can be performed [317] while in other cases, urethroplasty is warranted.

4.4.3.2.2 Penetrating posterior urethral injuries

The management of penetrating posterior urethral injuries is mainly dependent on associated injuries and the clinical condition of the patient [197, 281]. If possible, immediate exploration by the retropubic route and primary repair or re-alignment can be performed [197, 281, 287]. In the case of rectal injury, a diverting colostomy is necessary [197, 281]. Life-threatening associated injuries often preclude direct urethral repair. In those cases, suprapubic diversion with delayed abdominoperineal urethroplasty is advised [197, 273, 281].

4.4.3.2.2.1 Female urethral injuries

Proximal and mid-urethral disruptions require immediate exploration and primary repair using the retropubic and transvaginal routes, respectively, with primary suturing of the urethral ends. Concomitant vaginal lacerations are repaired transvaginally at the same time [191, 265, 268, 288]. Distal urethral injuries can be managed vaginally by primary suturing and closure of the vaginal laceration [265, 288]. In all of these operations, it is advisable to use a flap (e.g. Martius) to prevent urethrovaginal fistulas [327]. Nonetheless, distal urethral injuries can be left unrepaired and hypospadiac since they do not disrupt the sphincteric mechanism [191, 265, 268, 288].

4.4.3.2.2.1.1 Iatrogenic urethral injuries

Temporary stenting with an indwelling catheter is the conventional treatment option for an acute false passage [328], although its value in minor urethral injuries is unproven. In difficult cases, catheter insertion may be assisted by cystoscopy and guidewire placement [329]. Suprapubic catheterisation is an alternative.

Endoscopic management, either with incision or resection, can successfully treat iatrogenic prostatic urethral strictures. Indwelling catheter placement or an open procedure (which is associated with increased morbidity) are alternatives [330].

Urethral lesions following radiotherapy are often more difficult to treat and may require complex reconstructive surgery [257, 258]. Section 4.4.4.1 lists the summary of evidence and recommendations for the management of iatrogenic urethral trauma.

4.4.3.3 Treatment algorithms

The following algorithms are suggested for the treatment of anterior and posterior urethral injuries in men (Figures 4.4.1 and 4.4.2).

Figure 4.4.1: Management of anterior urethral injuries in men

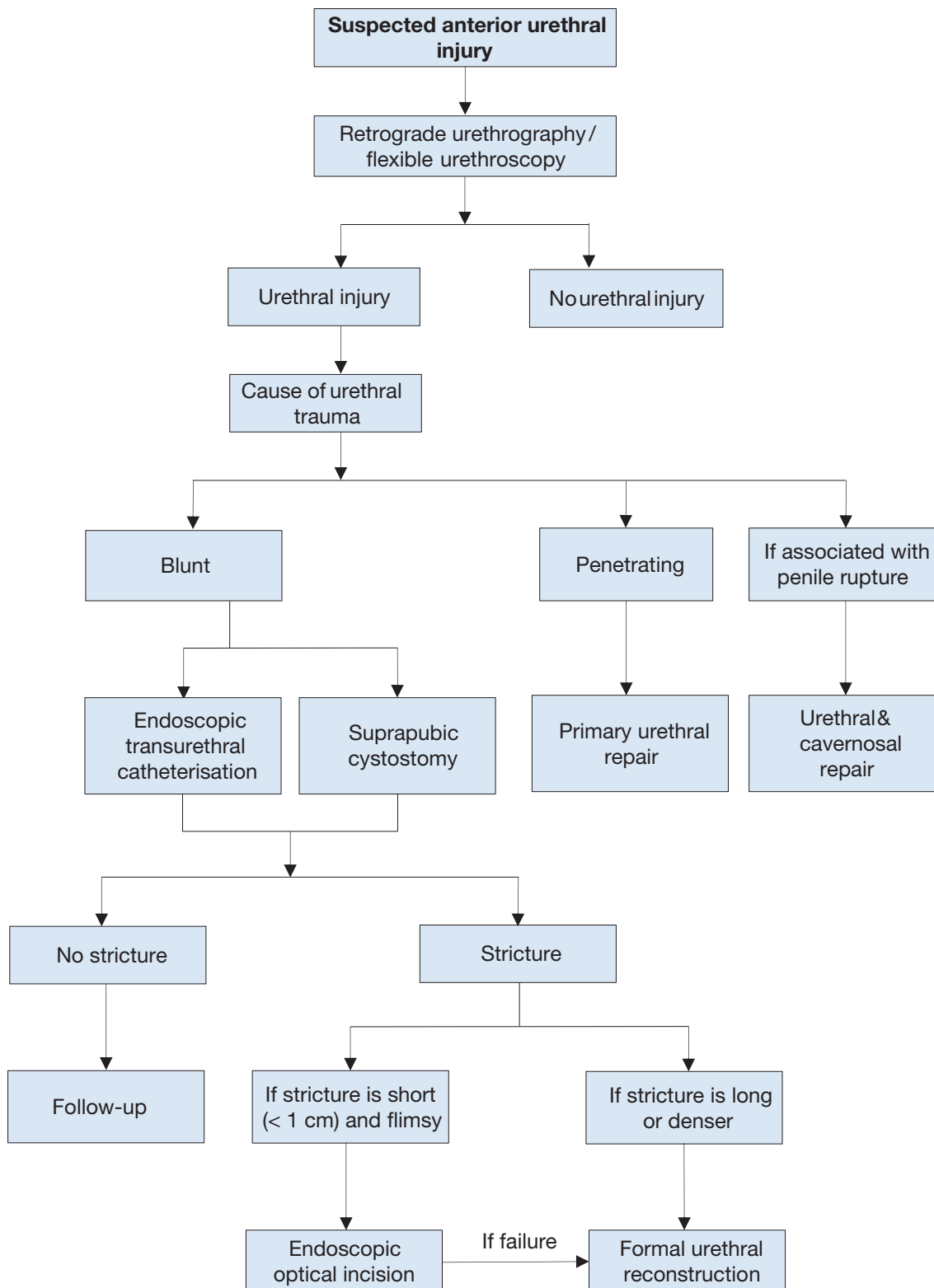


Figure 4.4.2: Management of posterior urethral injuries in men

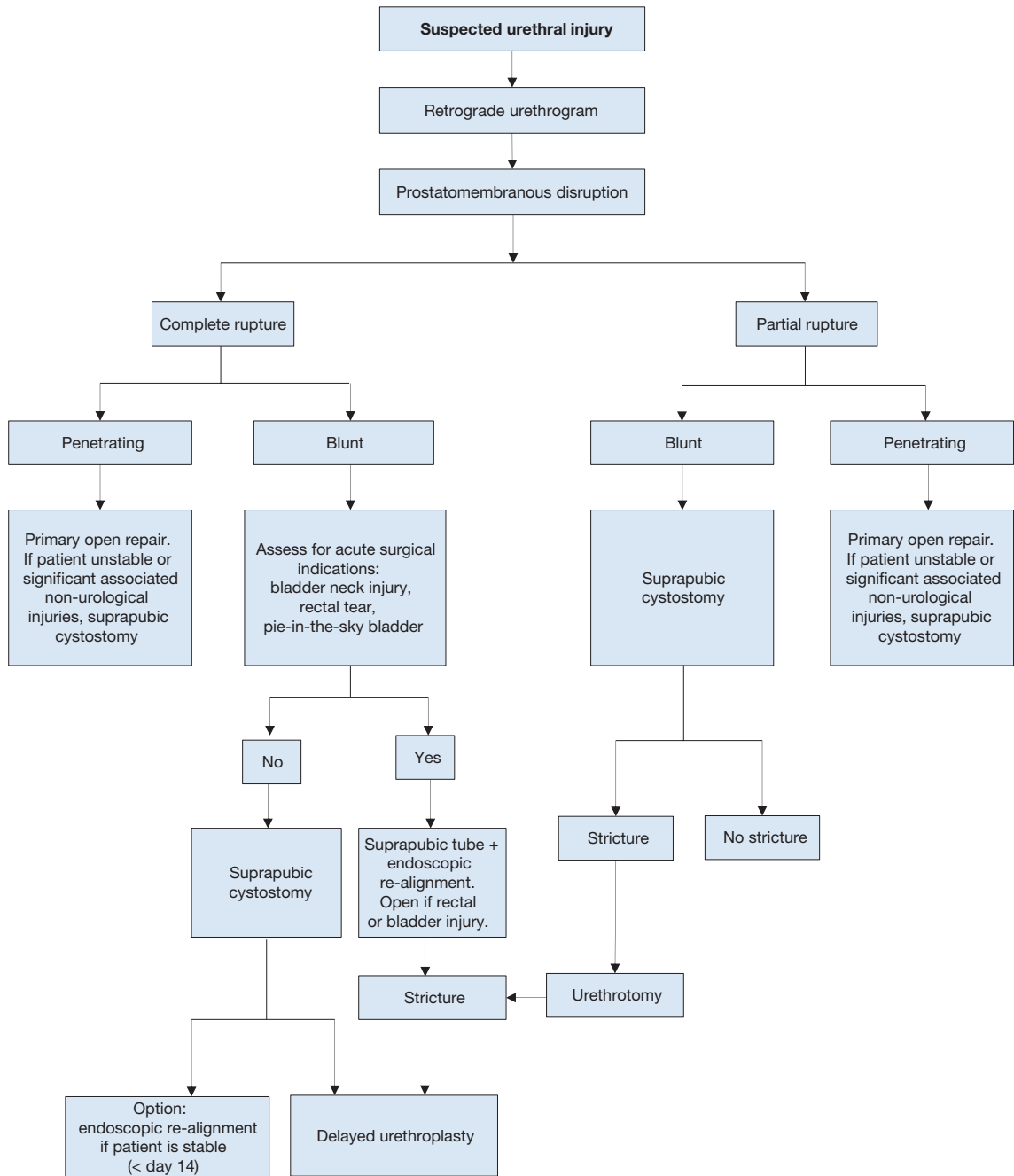


Figure 4.4.3: Treatment of iatrogenic urethral injury caused by improper insertion of a catheter

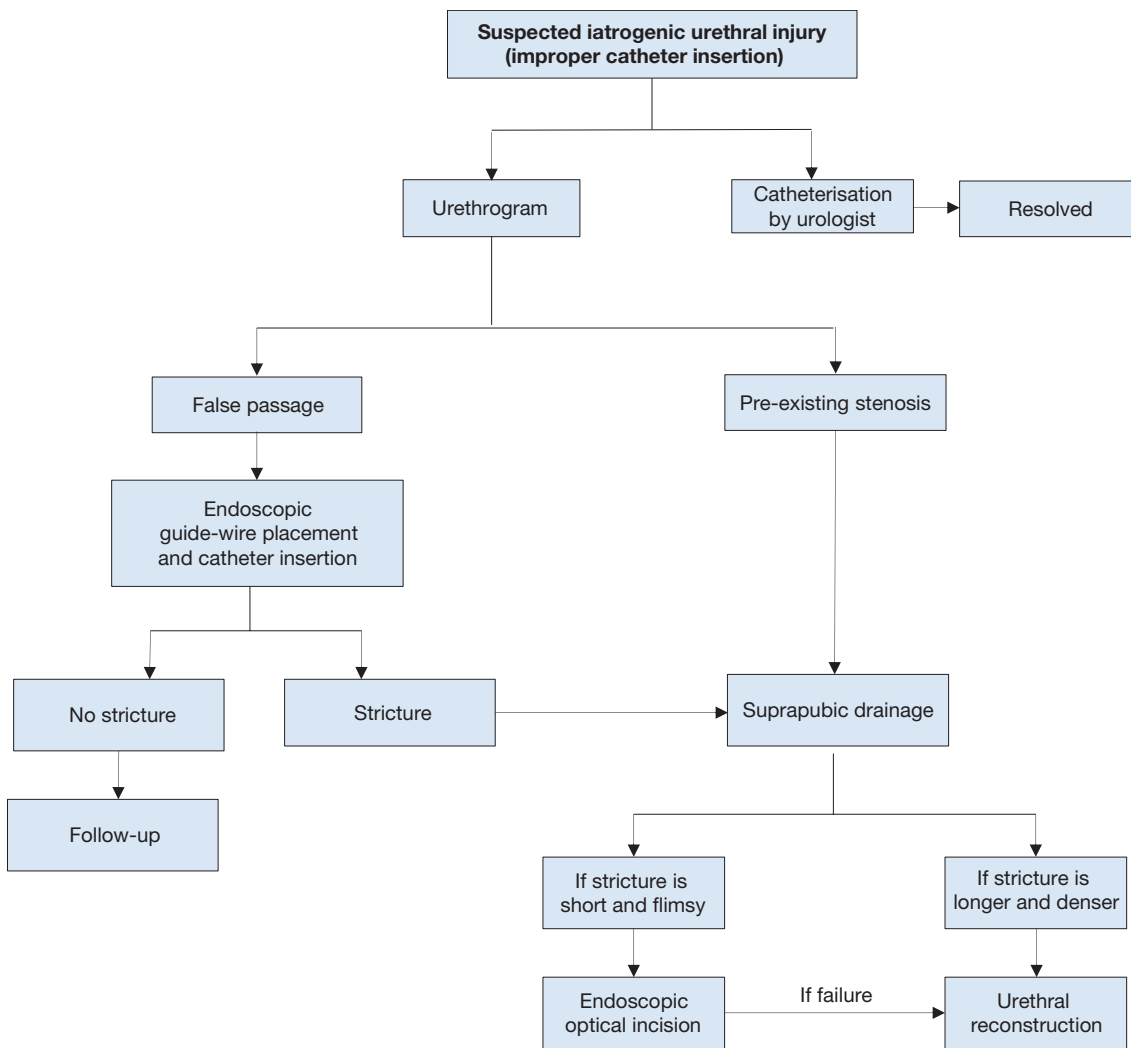
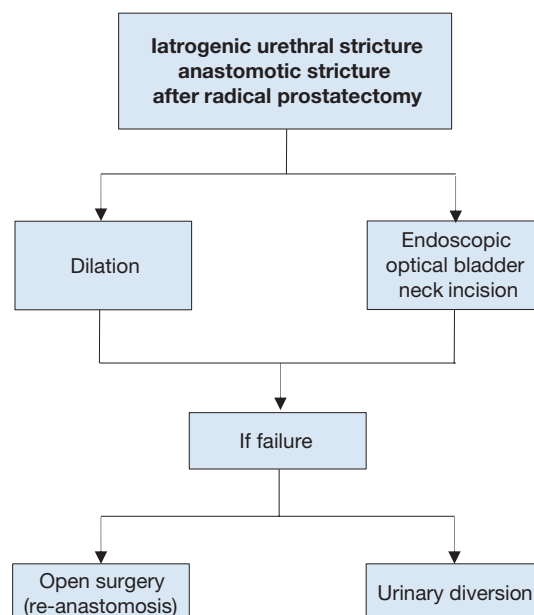


Figure 4.4.4: Treatment for stricture after radical prostatectomy



4.4.4 Summary of evidence and recommendations for the management of urethral trauma

Summary of evidence	LE
Blunt trauma accounts for more than 90% of urethral injuries.	3
In penile fracture, the urethra is involved in 20% of cases.	4
The male posterior urethra is injured in 4-19% of pelvic fracture cases. In industrialised societies pelvic fracture-related injuries of the posterior urethra are the most common non-iatrogenic injuries.	3
Erectile dysfunction occurs in 20-60% of patients after traumatic urethral rupture.	3

Recommendations	Strength rating
Evaluate urethral injuries with flexible cystoscopy and/or retrograde urethrography.	Strong
Treat blunt anterior urethral injuries by suprapubic diversion.	Strong
Treat partial posterior urethral ruptures by urethral or suprapubic catheterisation.	Strong
Perform early endoscopic re-alignment when feasible.	Weak
Manage complete posterior urethral disruption with suprapubic diversion and deferred (at least three months) urethroplasty.	Strong

4.4.4.1 Summary of evidence and recommendations for the management of iatrogenic urethral trauma

Summary of evidence	LE
Iatrogenic causes are the most common type of urethral injury in Europe, and therefore the most common cause of urethral stricture formation.	2a
Implementing training programmes on urinary catheter insertion significantly improves the rate of catheter-related complications.	3
New technologies represent an additional source of urethral injury.	3

Recommendations	Strength rating
Provide appropriate training to reduce the risk of traumatic catheterisation.	Strong
Keep duration of catheterisation to a minimum.	Strong

4.5 Genital Trauma

4.5.1 Introduction and background

Genito-urinary trauma is seen in both sexes across all age groups. Of all urological injuries, 33-66% involve the external genitalia [21]. Genital trauma is much more common in males than in females, especially between the ages of 15 and 40 years. This is due to anatomical differences, increased frequency of road traffic accidents and increased participation in physical sports, war and violent crime.

Genital trauma is commonly caused by blunt injuries (80%). The risk of associated injuries to neighbouring organs (bladder, urethra, vagina, rectum and bowel) after blunt trauma is higher in females than in males. In males, blunt genital trauma frequently occurs unilaterally with only approximately 1% presenting as bilateral scrotal or testicular injuries [331].

Any kind of contact sport, without the use of necessary protective aids, may be associated with genital trauma. Off-road bicycling, motorbike riding (especially on motorbikes with a dominant petrol tank), rugby, football and hockey are all activities which are associated with blunt testicular trauma [332-335].

Penetrating injuries account for 20% of genito-urinary trauma, with 40-60% of all penetrating genito-urinary lesions involving the external genitalia [270, 336]. Thirty-five per cent of all genito-urinary gunshot wounds involve the genitalia [331]. In a recent series of wartime genito-urinary injuries, 71.5% of 361 operations involved the external genitalia - the majority caused by IEDs and other explosive ordinance, while smaller numbers of injuries were due to gunshot injuries [337]. In both males and females, penetrating genital injuries occur with other associated injuries in 70% of patients. In males, penetrating scrotal injuries affect both testes in 30% of cases compared with 1% in blunt scrotal injuries [331, 338]. Self-mutilation of the external genitalia has also been reported in psychotic patients and transsexuals [339]. Genital burns are rare in isolation, usually due to industrial flame or chemicals in adults, and all but the full thickness type are treated conservatively [340]. Both male and female genital piercings increase the risk for unexpected genital trauma [341]. Although there is an increased risk of hepatitis B and C in genitally injured patients, there is no higher incidence of sexual transmitted diseases (STDs) in patients with genital piercings [341].

4.5.2 **General principles and pathophysiology**

In genital trauma, a urinalysis should be performed. The presence of visible- and/or non-visible haematuria requires a retrograde urethrogram in males. In females, flexible or rigid cystoscopy has been recommended to exclude urethral and bladder injury [342, 343]. In women with genital injuries and blood at the vaginal introitus, further gynaecological investigation is needed to exclude vaginal injuries [343]. The potential for significant injury should never be discounted in those patients who may also have blood in the vaginal vault from menstruation. Complete vaginal inspection with specula is mandatory.

4.5.2.1 *Gunshot wounds*

In patients with genitalia injured by gunshot wounds, it is very useful to have information about the causative weapon, particularly the range, calibre and type of weapon. High-velocity missiles transmit large amounts of energy to the tissues and can produce trauma to structures outside the wound track. The passage of a missile creates an expansive cavity of sub-atmospheric pressure, which then collapses and creates shear forces and induction of other foreign bodies and (usually) infected material [21].

4.5.2.2 *Bites*

4.5.2.2.1 *Animal bites*

Although animal bites are common, bites injuring the external genital are rare. Wounds are usually minor, but have a risk of wound infection. The most common bacterial infection caused by a dog bite is *Pasturella multocida*, which accounts for up to 50% of infections [344]. Other commonly involved organisms are *Escherichia coli*, *Streptococcus viridans*, *Staphylococcus aureus*, *Eikenella corrodens*, *Capnocytophaga canimorsus*, *Veillonella parvula*, *Bacteroides* and *Fusobacterium spp.* [339, 344, 345]. Antibiotics should be prescribed in accordance with local resistance patterns [346-348].

The possibility of rabies infection must be considered. If rabies infection is suspected, vaccination should be considered taking into account the geographical location, animal involved, specific nature of the wound and the type of attack (provoked/unprovoked). Besides vaccination, local wound management is an essential part of post-exposure prophylaxis. High-risk patients should be vaccinated with human rabies immunoglobulin and human diploid cell vaccine [349, 350].

4.5.2.2.2 *Human bites*

Human bites are much less common, but infection should be considered, especially in at risk groups. Since transmission of viral diseases may occur, risk assessment should be made. If appropriate, hepatitis B vaccine/immunoglobulin and/or immunodeficiency virus (HIV) post-exposure prophylaxis should be offered. For further details, see Guidelines for the Management of Human Bite Injuries [351].

4.5.2.3 *Sexual activity*

4.5.2.3.1 *Sexual intercourse*

Accidents during sexual intercourse can cause genital trauma, men of younger age are the most affected. The major pathologies are: penile fractures, strangulation and necrosis, and urethrovesical foreign bodies resulting from autoeroticism practices [352].

4.5.2.3.2 *Sexual assault*

Genital injury is often seen (42%) after sexual abuse, which must be considered when genital injuries present at any age [353]. In these cases, the examiner should be aware of the extraordinary emotional situation of the patient and the privacy of the patient should be respected. In suspicious cases, gynaecological and forensic support and advice is necessary. Swabs or vaginal smears should be taken for detection of spermatozoa [354] and local legal protocols followed closely. A thorough history and examination (in some cases under anaesthesia), photo documentation, and identification of forensic material may be important. In a recent report, only 38% of the forensic samples tested positive for an ejaculate and/or sperm. This may be due to delayed presentation or lack of vaginal/anal ejaculation [355].

4.5.3 *Organ-specific genital trauma*

4.5.3.1 *Penile trauma*

4.5.3.1.1 *Blunt penile trauma*

Blunt trauma to the flaccid penis does not usually cause tearing of the tunica. In these cases, only subcutaneous haematoma with intact tunica albuginea may be seen.

4.5.3.1.1.1 *Penile fracture*

The most important and common presentation of blunt penile trauma is penile fracture. A recent meta-analysis on penile fractures showed that the most common causes are sexual intercourse, forced flexion (taqaandan),

masturbation and rolling over in 46%, 21%, 18 % and 8.2% respectively [356]. The most common mechanism of injury is when the penis slips out of the vagina and strikes against the symphysis pubis or perineum. Sixty per cent of cases occur during consensual intercourse [357], with penile fracture more likely when the partner is on top. Penile fracture is caused by rupture of the cavernosal tunica albuginea, and may be associated with subcutaneous haematoma and lesions of the corpus spongiosum or urethra in 10-22% [358-360].

The thickness of the tunica albuginea in the flaccid state (approximately 2 mm) decreases in erection to 0.25-0.5 mm, and is therefore more vulnerable to traumatic injury [361, 362]. Penile fracture is associated with a sudden cracking or popping sound, pain and immediate detumescence. Local swelling of the penile shaft develops quickly, due to enlarging haematoma. Bleeding may spread along the fascial layers of the penile shaft and extend to the lower abdominal wall if Buck's fascia is also ruptured. Sometimes, the rupture of the tunica may be palpable. Less severe penile injuries can be distinguished from penile fracture, as they are not usually associated with detumescence [356].

A thorough history and examination usually confirm the diagnosis, but in some cases imaging may be useful. Cavemosography, US or MRI [356, 363-365] can identify lacerations of the tunica albuginea in unclear cases [366], or provide reassurance that the tunica is intact. If a concomitant urethral injury is suspected, a retrograde urethrogram may be performed, however, flexible cystoscopy under anaesthesia during exploration/repair is more usually employed.

Subcutaneous haematoma, without associated rupture of the cavernosal tunica albuginea, does not require surgical intervention. In these cases, non-steroidal analgesics and ice-packs are recommended [367].

When a penile fracture is diagnosed, surgical intervention with closure of the tunica albuginea is recommended, it ensures the lowest rate of negative long-term sequelae and has no negative effect on the psychological wellbeing of the patient [368]. The approach is usually through a circumferential incision proximal to the coronal sulcus which enables complete degloving of the penis. Increasingly, local longitudinal incisions centred on the area of fracture or ventral longitudinal approaches are currently used [293]. Further localisation may be gained with a flexible cystoscopy performed prior to incision, if urethral trauma is suspected and eventually proven.

Surgical closure of the tunica should be carried out using absorbable sutures. Post-operative complications were reported in up to 20% of cases, development of plaques or nodules following surgery, post-operative curvature formation and ED occur in 13.9%, 2.8% and 1.9% of patients, respectively [356]. Conservative management of penile fracture is not recommended, as it significantly increases the rate of post-operative complications [356]. It increases complications, such as penile abscess, missed urethral disruption, penile curvature, and persistent haematoma requiring delayed surgical intervention [369]. Late complications after conservative management were fibrosis and angulations in 35% and impotence in up to 62% [357, 369].

4.5.3.2 *Penetrating penile trauma*

Penetrating penile trauma is rarely seen in isolation. Most cases are associated with multiple injuries. Non-operative management is recommended in small superficial injuries with intact Buck's fascia [270]. In more significant penetrating penile injuries, surgical exploration and debridement of necrotic tissue is recommended. Even in extended injuries of the penis, primary alignment of the disrupted tissues may allow for acceptable healing because of the robust penile blood supply [339].

The principles of care are debridement of devitalised tissue, with the preservation of as much viable tissues as possible, haemostasis, diversion of urine in selected cases and the removal of foreign bodies. Tissues of questionable viability may be left for subsequent definitive surgery. If a subsequent immediate or delayed repair is needed, depending on the type of injury and the extent of tissue damage, it usually takes place four to six weeks after the trauma has occurred.

The surgical approach depends upon the site and extent of the injury, but a subcoronal incision with penile degloving usually gives good exposure. Initially, a defect in the tunica albuginea should be closed after copious irrigation. If there has been too much tissue loss, the defect can be repaired either immediately or after delay with a patch (either from an autologous saphenous vein or xenograft). If a concomitant urethral injury is suspected, a pre- or peri-operative urethrogram or cystoscopy is useful to diagnose any urethral involvement, to define its position, and to decide upon the incision used.

The elasticity of genital skin means it is usually possible to manage the loss of a moderate amount of penile skin. However, management is more difficult in extensive injuries with significant skin loss. The tissue chosen

for reconstruction following trauma needs to provide good coverage and must be suitable for reconstruction. Split-thickness skin grafting provides good coverage and a dependable take that is reproducible and durable. However, split-thickness grafts contract more than full-thickness grafts and their use on the penile shaft should be kept to a minimum. In accordance, McAninch *et al.* recommended the use of skin grafts with thickness of at least 0.015 inch (0.4 mm) in order to reduce the risk of contraction [339]. Full-thickness skin grafting onto the penile shaft gives less contracture, a better cosmetic appearance and more resistance to trauma during intercourse, when eventually re-established [367]. The donor site may be taken from the abdomen, buttock, thigh or axilla and is chosen according to surgeon's preference and the pattern of injury.

In cases of extensive destruction of deeper tissues, or if later prosthetic placement is being considered, skin flaps, with their secure vascular supply, can be used.

4.5.3.3 *Penile avulsion injuries and amputation*

Most injuries are self-inflicted, but some are a result of industrial accidents or assault. Acute management involves resuscitation of the patient, who may be compromised from massive blood loss, and preparation for surgical re-implantation of the penis if it has been recovered and is not too badly damaged. Surgical re-implantation should be considered for all patients and should be performed within 24 hours of amputation. If the injury occurred during a psychotic episode, early psychiatric advice and support should be sought [370].

The severed penis should be washed with sterile saline, wrapped in saline-soaked gauze, placed in a sterile bag and immersed in iced water. The penis must not come into direct contact with the ice. A pressure dressing or a tourniquet should be placed around the penile stump to prevent excessive blood loss. Re-attachment can be achieved in a non-microsurgical way, a technique which probably gives higher rates of post-operative urethral stricture and more problems with loss of sensation [371]. When operating microscopically, the corpora cavernosa and urethra are firstly aligned and repaired. Subsequently, the dorsal penile arteries, the dorsal vein and the dorsal nerves are anastomosed. The cavernosal arteries are generally too small to anastomose. The fascia and skin are closed in layers and both a urethral and a supra-pubic catheter are placed.

If the severed penis cannot be found, or is unsuitable for re-attachment, then the end should be closed as it is done in partial penectomy. Later reconstruction may be employed to lengthen the penis (e.g. suspensory ligament division and V-Y plasty, pseudo-glans formation with split-thickness skin grafting, etc.). A delayed major reconstructive procedure, i.e. phalloplasty (either radial artery or pubic), is sometimes required for injuries which leave a very small or non-functioning penile stump [370].

4.5.4 **Scrotal trauma**

4.5.4.1 *Blunt scrotal trauma*

Blunt trauma to the scrotum can cause testicular dislocation, testicular haematocoele, testicular rupture and/or scrotal haematoma.

4.5.4.1.1 Testicular dislocation

Traumatic dislocation of the testicle rarely occurs and is most common in victims of MVAs [372-375]. Bilateral dislocation of the testes has been reported in up to 25% of cases [373]. It can be either a subcutaneous dislocation with epifascial displacement of the testis or an internal dislocation. In the latter, the testis is positioned in the superficial external inguinal ring, inguinal canal or abdominal cavity. Traumatic dislocation of the testis is treated by manual replacement and secondary orchidopexy. If primary manual reposition cannot be performed, immediate orchidopexy is indicated.

4.5.4.1.2 Haematocoele

Conservative management is recommended in haematocoeles smaller than three times the size of the contralateral testis [376]. In large haematocoeles, non-operative management can fail, and delayed surgery (more than three days) is often required. Patients with large haematocoeles have a higher rate of orchietomy than patients who undergo early surgery, even in non-ruptured testes [331, 339, 377-379]. Early surgical intervention results in preservation of the testis in more than 90% of cases compared to delayed surgeries which result in orchietomy in 45-55% of patients [379]. In addition, non-operative management is also associated with prolonged hospital stays. Therefore, large haematocoeles should be treated surgically, irrespective of the presence of testicular contusion or rupture. At the very least, the blood clot should be evacuated from the tunica vaginalis sac to relieve disability and hasten recovery. Patients initially treated non-operatively may eventually need delayed surgery if they develop infection or undue pain.

4.5.4.1.3 Testicular rupture

Testicular rupture is found in approximately 50% of cases of direct blunt scrotal trauma [379, 380]. It may occur under intense, traumatic compression of the testis against the inferior pubic ramus or symphysis, resulting in a rupture of the tunica albuginea of the testis. A force of approximately 50 kg is necessary to cause testicular rupture [381]. Testicular rupture is associated with immediate pain, nausea, vomiting, and sometimes fainting. The hemiscrotum is tender, swollen, and ecchymotic. The testis itself may be difficult to palpate.

Ultrasound should be performed to determine intra- and/or extra-testicular haematoma, testicular contusion, or rupture [380, 382-390]. However, the literature is contradictory as to the usefulness of US compared to clinical examination alone. Some studies have reported convincing findings with a specificity of up to 98.6% [362]. Others reported poor specificity (78%) and sensitivity (28%) for the differentiation between testicular rupture and haematocele, while accuracy is as low as 56% [383]. Colour Doppler-duplex US may provide useful information when used to evaluate testicular perfusion. If scrotal US is inconclusive, testicular CT or MRI may be helpful [391]. However, these techniques did not specifically increase the detection rates of testicular rupture. It is therefore essential to surgically explore equivocal patients whenever imaging studies cannot definitively exclude testicular rupture. This involves exploration with evacuation of blood clots and haematoma, excision of any necrotic testicular tubules and closure of the tunica albuginea, usually with running absorbable sutures (e.g. 3/0 Vicryl).

4.5.4.2 Penetrating scrotal trauma

Penetrating injuries to the scrotum require surgical exploration with conservative debridement of non-viable tissue. Depending on the extent of the injury, primary reconstruction of the testis and scrotum can usually be performed. In complete disruption of the spermatic cord, re-alignment without vaso-vasostomy may be considered if surgically feasible [392]. Staged secondary microsurgical vaso-vasostomy can be performed after rehabilitation, although only a few cases have been reported [392]. If there is extensive destruction of the tunica albuginea, mobilisation of a free tunica vaginalis flap can be performed for testicular closure. If the patient is unstable or reconstruction cannot be achieved, orchiectomy is then indicated.

Prophylactic antibiotics are recommended after scrotal penetrating trauma, although data to support this approach is lacking. Tetanus prophylaxis is mandatory. Post-operative complications were reported in 8% of patients who underwent testicular repair after penetrating trauma [270].

Extended laceration of scrotal skin requires surgical intervention for skin closure. Due to the elasticity of the scrotum, most defects can be primarily closed, even if the lacerated skin is only minimally attached to the scrotum [339]. Local wound management with extensive initial wound debridement and washout is important for scrotal convalescence. In the case of extensive loss of genital tissue, e.g. IED blast injury, complex and staged reconstructive surgical procedures are often required [337].

4.5.5 Genital trauma in females

In females with blunt trauma to the external genitalia, imaging of the pelvis with US, CT, or MRI should be performed since additional injuries and extensive intra-pelvic haematomas are frequently expected [343, 354].

4.5.5.1 Coital injury of the female genital tract

Consensual sexual intercourse can lead to genital trauma in women. Up to 35% of all genital injuries in women are sustained during their first sexual contact. The majority of women present with bleeding and pain. The most frequently found injuries are lacerations. These lesions can be treated with a simple suture under local anesthesia [393].

4.5.5.2 Blunt vulvar injuries

Blunt trauma to the vulva is rarely reported and usually presents as a large haematoma. The incidence of traumatic vulvar haematomas after vaginal deliveries has been reported as 1 in 310 deliveries [394]. Although blunt trauma to the female external genitalia is rarely reported, the presence of a vulvar haematoma is closely related to an increased risk of associated vaginal, pelvic or abdominal injuries. Goldman *et al.* reported that blunt injuries of the vulva and vagina were associated with pelvic trauma in 30%, after consensual intercourse in 25%, following sexual assault in 20%, and other blunt trauma in 15% [342].

Blunt vulvar or perineal trauma may be associated with voiding problems and bladder catheterisation is usually required. Vulvar haematomas usually do not require surgical intervention, although they can cause significant blood loss, which sometimes even requires blood transfusion. Data are scarce [395], but in haemodynamically stable women, non-steroidal anti-inflammatory medication and cold packs are generally successful. In cases

of massive vulvar haematoma and haemodynamically unstable patients, surgical intervention with lavage and drainage is sometimes indicated [396].

Although antibiotics are often recommended after major vulvar trauma, there is no data to support this approach. It is important to emphasise that vulvar haematoma and/or blood at the vaginal introitus are indications for vaginal exploration under sedation or general anaesthesia. The aim is to identify possible associated vaginal and/or rectal injuries [343]. Flexible or rigid cystoscopy has been recommended to exclude urethral and bladder injury [342, 343]. In the case of vulvar laceration, suturing after conservative debridement is indicated. If there are associated injuries to the vagina, these can be repaired immediately by primary suturing.

4.5.6 *Summary of evidence and recommendations for the management of genital trauma*

Summary of evidence	LE
Most genital injuries, in males and females, are caused by blunt trauma.	3

Recommendations	Strength rating
Treat penile fractures surgically, with closure of tunica albuginea.	Strong
Explore the injured testis in all cases of testicular rupture and in those with inconclusive ultrasound findings.	Weak

5. POLYTRAUMA, DAMAGE CONTROL AND MASS CASUALTY EVENTS

5.1 Introduction

Urological trauma is often associated with significant and higher priority injuries in the polytraumatised patient [397]. Lessons from civilian trauma networks, the battlefield, and mass casualty events have led to many advances in general trauma care [398, 399]. These include the widespread acceptance of damage control principles, trauma centralisation and recognition of the value of dedicated trauma teams. Urologists need to understand their role in the context of polytrauma with the ultimate aims of improving survivability and decreasing morbidity in these patients.

5.1.1 *The development of major trauma centres*

Multidisciplinary management of trauma patients has been shown to improve outcomes [400]. Major trauma patients initially managed in local hospitals are 1.5-5 times more likely to die than patients transported directly to specialist trauma centres. The re-organisation of care to these centres has been shown to reduce mortality by 25% and length of stay by four days [398]. Major trauma centres, which are expected to provide senior led resuscitative trauma teams, dedicated trauma theatres, input from all major surgical specialties and interventional radiologists, have therefore been established worldwide. Urologists have an important role to play in this process [401].

5.1.1.1 *Summary of evidence and recommendations for polytrauma management*

Summary of evidence	LE
Urological trauma is often associated with higher priority injuries in a polytrauma setting.	2
The overall mortality is lower for polytrauma patients when care is provided in a designated trauma centre.	3
Urologists have an important role in the multi-disciplinary management of polytrauma.	4

Recommendations	Strength rating
Manage polytrauma patients in designated major trauma centres within a trauma network.	Strong
Involve urologists in cases of associated urological injury.	Strong

5.2 Damage control

Damage control is a life-saving strategy for severely injured patients that recognises the consequences of the lethal triad of trauma, i.e. hypothermia, coagulopathy and acidosis [402-404].

It is a prioritised three-phase approach:

- the first phase consists of rapid control of haemorrhage and wound contamination;
- the second phase involves resuscitation in the intensive care unit (ICU), with the goal of restoring normal temperature, coagulation, and tissue oxygenation;
- the third stage involves definitive surgery when more time-consuming reconstructive procedures are performed in the stabilised patient [405].

Identifying which patients benefit from the damage control mode requires critical decision-making by the trauma team leader. Prior preparedness and regular communication between the surgical, critical care and anaesthetic teams are vital [406]. Damage control principles have been successfully adopted in the context of civilian mass casualty events, military field surgery, and initial treatment in rural areas with long-range transfers [403, 407].

5.3 Management principles: polytrauma and associated urological injury

Urologists are often asked for advice in polytrauma patients, some of whom might be in a damage control phase of management. Fortunately, the management of urological trauma often involves the use of temporary measures, followed by later definitive surgery, which fits in well with these principles. In the polytrauma setting, the urologist will usually work alongside the general/trauma surgeon. Procedures should be directed at the rapid control of bleeding, debridement of dead and devitalised tissue, and minimising urinary extravasation by simple diversionary measures. Complex reconstructive procedures, including organ preservation, are preferably delayed.

Examples where urological input is required in the polytraumatised patient include:

- haemodynamically unstable patients with suspected intra-abdominal bleeding, who are transferred urgently to the operating theatre without any pre-operative imaging;
- stable patients with suspected renal injuries-penetrating trauma to the upper abdomen/flanks/lower chest, or blunt abdominal trauma and visible haematuria;
- patients with suspected urethral or bladder injury associated with pelvic fractures; blood at the urethral meatus and/or the inability to void;
- external genitalia injury associated with penetrating trauma (intra-abdominal injury).

5.3.1 Summary of evidence and recommendations for management principles of polytrauma and associated urological injury

Summary of evidence	LE
Damage control principles should govern the management of the severely injured polytrauma patient.	4

Recommendations	Strength rating
Follow damage control principles in the management of severe polytrauma patients.	Strong

5.4 Urological injury management in polytrauma

5.4.1 Renal injury

The incidence of multi-organ injury is high in penetrating trauma [33]. Most of these injuries can be managed without surgical exploration [30]. Renal exploration is required to control life-threatening bleeding [408]. The preservation of viable renal parenchyma is a secondary goal, with time-consuming renal reconstruction delayed until the patient is optimised [113].

At laparotomy, it is considered best practice not to explore the injured kidney if there is no active haemorrhage, even if delayed exploration is then necessary [78]. In unstable patients, packing the renal fossa and transferring the patient to the surgical intensive care unit is the option of choice for damage control. A planned second-look laparotomy is then performed [181]. However, in patients with significant ongoing haemorrhage, speedy nephrectomy is required. It is recommended that the contralateral kidney should at least be palpated prior to nephrectomy [409].

In patients who are packed temporarily and who become sufficiently stable in the intensive care

setting, radiological assessment allows definitive management to begin. Computed tomography allows the kidney injury to be graded, documents the presence of a contralateral kidney, and helps to determine whether or not intervention (radiological or surgical) is necessary.

In patients who are haemodynamically unstable after the initial acute-damage-control laparotomy, or in patients with deteriorating haemodynamic parameters (indicating ongoing or delayed bleeding), the management options are angiographic embolisation of the bleeding kidney or re-operation [410]. This decision should be made according to:

- the status of the patient;
- the presence of associated injuries (stapled bowel, packed liver or spleen), which may need re-operation irrespective of the renal injury;
- the availability of angioembolisation.

5.4.1.1 Renal preservation

Haemostatic techniques, many of which were developed for hepatic surgery and splenic trauma, can be used to control renal parenchymal bleeding. These techniques are not consistent with damage control principles and should only be considered in the rare casualty situation of a solitary kidney or bilateral renal injury. These techniques are outlined below:

- mattress sutures through the parenchyma, i.e. renorrhaphy [181];
- haemostatic agents, i.e. combined acellular matrix and fibrin sealants [115];
- absorbable mesh kidney bags to maintain contact between renal parenchymal fragments [108];
- intra-operative drain left *in situ* to collect any urine that leaks following organ salvage.

5.4.1.2 Summary of evidence and recommendations for the management of renal injury

Summary of evidence	LE
Angioembolisation has an important role in haemostasis of renal injuries in a polytrauma setting.	3

Recommendations	Strength rating
Manage life-threatening bleeding from renal injury by urgent nephrectomy.	Strong
Manage profuse non-arterial bleeding by renal packing as a damage control measure.	Weak
Use angioembolisation when possible as an effective haemostatic measure.	Strong

5.4.2 Ureteral injury

Ureteral injuries are primarily associated with penetrating intra-abdominal injury; although rapid deceleration injuries can also result in ureteropelvic disruption [165]. A high index of suspicion is required as these injuries are quite commonly missed [411]. The results of immediate ureteral reconstruction are generally satisfactory, but this is time-consuming and may not be appropriate in the polytraumatised patient. Diagnostic procedures, such as on-table IVP or retrograde ureteropyelography to evaluate ureteral injuries are also not recommended in this setting.

If a ureteral injury is suspected but not clearly identified, a drain should be sited. If urine leaks post-operatively, a nephrostomy should be arranged. If a partial ureteral tear is identified (less than half a circumference) and the ureter is otherwise healthy, a double J-stent may be inserted over a guide wire through the tear, and the tear quickly closed with fine interrupted absorbable stitches.

When complete ureteral injuries are identified, definitive repair should not be performed. Dissection of the ureteral stumps should be avoided as it interferes with the blood supply. Temporary measures to control urine spillage should be performed:

- a single J or 8 French feeding tube is inserted into the ureter;
- the end of the disrupted proximal ureter is secured over the tube, which is exteriorised and secured to the skin.

The distal ureteral stump does not need to be ligated and any unnecessary manipulation should be avoided. Intra-operative placement of a nephrostomy tube is time-consuming and should be avoided [113, 181]. Tying off the injured ureteral segment and inserting a percutaneous nephrostomy post-operatively is a viable alternative [412]. Rarely, in cases with severe associated injuries of the ipsilateral kidney, nephrectomy is required.

5.4.2.1 Recommendations for the management of ureteral injury

Summary of evidence	LE
A high index of suspicion for ureteral injuries is required.	4
When complete ureteral injuries are identified, definitive repair should be avoided and temporary measures to control urinary spillage are recommended.	4

Recommendations	Strength rating
Treat ureteral injury with 'tube' urinary diversion if repair is not performed.	Strong

5.4.3 Bladder trauma

In the acute polytrauma setting, a bladder injury should be treated with bladder drainage by a suprapubic and/or a urethral catheter. Later, definitive treatment can follow as necessary [413]. Ideally, large intraperitoneal bladder ruptures (often associated with unstable pelvic fractures) should be closed primarily and drained, as this will cope with both haemorrhage control and urinary contamination.

Examples of temporary measures that may be necessary include:

- the placement of externalised ureteral stents to provide external urinary drainage in extensive bladder rupture [181];
- packing and/or arteriography and selective embolisation in unstable patients with severe bladder haemorrhage [181];
- the placement of a pelvic suction drain for urinary evacuation [181].

5.4.3.1 Recommendations for the management of bladder trauma and urethral injury

Summary of evidence	LE
Diversion of urine from site of injury is standard practice.	3

Recommendations	Strength rating
Provide urinary drainage by either the suprapubic or urethral route.	Strong

5.4.4 Urethral injury

Urethral injury of any kind is not life-threatening, but the associated injuries are often severe. In this situation, wherever the location or extent of injury, drainage through a suprapubic or urethral catheter should be obtained without prior imaging [264].

5.4.5 External genital injury

Traditionally, traumatic injuries of the external genitalia have a low priority and management is often deferred [414]. In the polytraumatised patient, the management of these injuries should be guided by the principles of haemorrhage control, debridement and urinary diversion (via a catheter). Delayed organ conservation is possible, particularly in testicular injury [415].

Temporary damage control measures that might be applicable include:

- compression dressing of the penis [181];
- packing of penetrating testicular injuries;
- tampons for vulvar lacerations.

5.5 Mass casualty events

A mass casualty event is one in which the number of injured people is significantly higher than the number of available healthcare providers [416]. A mass casualty disaster does not therefore necessarily involve a large number of victims, but it is related to the disproportion between the number of victims and the size of the medical team available [417, 418].

There are little published data on the best way in which to handle these events. However, recent developments in both the military and civilian settings have led to greater survivability following major trauma [419]. Triage, communication and preparedness are important components for a successful response.

Potential mass casualty events include:

- transportation systems accidents, e.g. road traffic, aircraft, shipping, railways;
- natural disasters, e.g. earthquakes, hurricanes, floods, tsunamis;
- industry, e.g. chemical spills, factory explosions and fires;
- civilian terrorism.

5.5.1 **Triage**

Triage after mass casualty events is difficult and involves difficult moral and ethical considerations. Disaster triage requires differentiation of the few critically injured individuals who can be saved by immediate intervention from the many others with non-life-threatening injuries for whom treatment can be delayed. The ethical dilemmas that arise are primarily caused by having to decide who should be actively treated, or subsequently whether to stop treatment, because of injuries deemed un-survivable or incompatible with survival in the home environment.

Triage sorts patients into four groups [420, 421]:

1. Patients with life-threatening injuries that require immediate intervention, presenting with airway compromise, breathing failure and/or circulatory compromise from ongoing external haemorrhage.
2. Patients with severe but non-life-threatening injuries, in whom treatment can be acceptably delayed, including those with major fractures, vascular injuries of the limbs and large soft tissue wounds.
3. 'Walking wounded', i.e. casualties with minimal injuries.
4. Patients who are so severely injured that treatment would require allocation of resources and time that would deny timely care to other patients with greater survivability. These patients are given minimal or no treatment, and are re-evaluated when resources become available. There is no absolute definition for this group because triage is individualised, according to the number and severity of casualties related to the available resources. The decision to implement this category is decided when sufficient information of the incident is available and is made at the highest level possible.

Triage should be performed at each stage from the pre-hospital setting to the emergency department and repeated as the clinical situation evolves. Ultimately, the individual in charge is responsible for directing specialty surgical teams, including urologists, and assigning them responsibility for specific patients as dictated by the specific injuries.

5.5.2 **Urological role in the mass casualty setting**

Urological consultations during a mass casualty scenario should follow the principles outlined below:

1. Rule out under-triage by the surgeon in charge, and perform a rapid primary survey of every patient.
2. Avoid unnecessary imaging procedures such as CT scans and retrograde urethrography. These procedures should be performed later, after re-evaluation of the patient, and after mass casualty protocols have been suspended.
3. Treat unstable patients who are to have surgery using damage control principles.
4. Stable patients should be transferred to the surgical ward without imaging procedures. Re-evaluate if there is any change in their haemodynamic status, or when possible as dictated by the constraints of the mass casualty event.
5. 'Minimal acceptable' treatment for all urological injuries should be performed in order to transfer patients to the surgical wards and are outlined above in the Section 5.4 Urological injury management in polytrauma.

6. REFERENCES

1. Tekgül, S., *et al.* EAU Guidelines on Paediatric Urology 2017. In: EAU Guidelines Edn. Presented at the EAU Annual Congress London 2017, European Association of Urology, Guidelines Office, Arnhem, The Netherlands.
<https://uroweb.org/guideline/paediatric-urology/>
2. Martinez-Pineiro, L., *et al.* EAU Guidelines on Urethral Trauma. *Eur Urol*, 2010. 57: 791.
<http://www.ncbi.nlm.nih.gov/pubmed/20122789>
3. Summerton, D.J., *et al.* EAU guidelines on iatrogenic trauma. *Eur Urol*, 2012. 62: 628.
<http://www.ncbi.nlm.nih.gov/pubmed/22717550>

4. Lumen, N., *et al.* Review of the current management of lower urinary tract injuries by the EAU Trauma Guidelines Panel. *Eur Urol*, 2015. 67: 925.
<http://www.ncbi.nlm.nih.gov/pubmed/25576009>
5. Serafetinides, E., *et al.* Review of the current management of upper urinary tract injuries by the EAU Trauma Guidelines Panel. *Eur Urol*, 2015. 67: 930.
<http://www.ncbi.nlm.nih.gov/pubmed/25578621>
6. Guyatt, G.H., *et al.* GRADE: an emerging consensus on rating quality of evidence and strength of recommendations. *BMJ*, 2008. 336: 924.
<http://www.ncbi.nlm.nih.gov/pubmed/18436948>
7. Guyatt, G.H., *et al.* What is "quality of evidence" and why is it important to clinicians? *BMJ*, 2008. 336: 995.
<http://www.ncbi.nlm.nih.gov/pubmed/18456631>
8. Phillips B, *et al.* Oxford Centre for Evidence-based Medicine Levels of Evidence. Updated by Jeremy Howick March 2009.
<http://www.cebm.net/oxford-centre-evidence-based-medicine-levels-evidence-march-2009/>
9. Guyatt, G.H., *et al.* Going from evidence to recommendations. *BMJ*, 2008. 336: 1049.
<http://www.ncbi.nlm.nih.gov/pubmed/18467413>
10. Soreide, K. Epidemiology of major trauma. *Br J Surg*, 2009. 96: 697.
<http://www.ncbi.nlm.nih.gov/pubmed/19526611>
11. Middleton, P., The trauma epidemic. In: Major Trauma Smith, J., Greaves, I., Porter, K. (2010) Oxford University Press: Oxford.
12. Thornley, S., *et al.* Alcohol intake, marijuana use, and sleep deprivation on the risk of falls occurring at home among young and middle-aged adults: a case-crossover study. *N Z Med J*, 2014. 127: 32.
<http://www.ncbi.nlm.nih.gov/pubmed/25447247>
13. Bergen, G., *et al.* Vital signs: health burden and medical costs of nonfatal injuries to motor vehicle occupants - United States, 2012. *MMWR Morb Mortal Wkly Rep*, 2014. 63: 894.
<http://www.ncbi.nlm.nih.gov/pubmed/25299606>
14. Baverstock, R., *et al.* Severe blunt renal trauma: a 7-year retrospective review from a provincial trauma centre. *Can J Urol*, 2001. 8: 1372.
<http://www.ncbi.nlm.nih.gov/pubmed/11718633>
15. Meng, M.V., *et al.* Renal trauma: indications and techniques for surgical exploration. *World J Urol*, 1999. 17: 71.
<http://www.ncbi.nlm.nih.gov/pubmed/10367364>
16. Bruce, L.M., *et al.* Blunt renal artery injury: incidence, diagnosis, and management. *Am Surg*, 2001. 67: 550.
<http://www.ncbi.nlm.nih.gov/pubmed/11409803>
17. Kuan, J.K., *et al.* Renal injury mechanisms of motor vehicle collisions: analysis of the crash injury research and engineering network data set. *J Urol*, 2007. 178: 935.
<http://www.ncbi.nlm.nih.gov/pubmed/17632156>
18. Pereira, B.M., *et al.* A review of ureteral injuries after external trauma. *Scand J Trauma Resusc Emerg Med*, 2010. 18: 6.
<http://www.ncbi.nlm.nih.gov/pubmed/20128905>
19. Bjurlin, M.A., *et al.* Genitourinary injuries in pelvic fracture morbidity and mortality using the National Trauma Data Bank. *J Trauma*, 2009. 67: 1033.
<http://www.ncbi.nlm.nih.gov/pubmed/19901665>
20. Dixon C.M., Diagnosis and acute management of posterior urethral disruptions, in Traumatic and reconstructive urology, McAninch, J.W. (1996) WB Saunders: Philadelphia.
21. Brandes, S.B., *et al.* External genitalia gunshot wounds: a ten-year experience with fifty-six cases. *J Trauma*, 1995. 39: 266.
<http://www.ncbi.nlm.nih.gov/pubmed/7674395>
22. Moore, E.E., *et al.* Organ injury scaling: spleen, liver, and kidney. *J Trauma*, 1989. 29: 1664.
<http://www.ncbi.nlm.nih.gov/pubmed/2593197>
23. Wutzler, S., *et al.* Association of preexisting medical conditions with in-hospital mortality in multiple-trauma patients. *J Am Coll Surg*, 2009. 209: 75.
<http://www.ncbi.nlm.nih.gov/pubmed/19651066>
24. Shoko, T., *et al.* Effect of pre-existing medical conditions on in-hospital mortality: analysis of 20,257 trauma patients in Japan. *J Am Coll Surg*, 2010. 211: 338.
<http://www.ncbi.nlm.nih.gov/pubmed/20800190>
25. Cline, K.J., *et al.* Penetrating trauma to the male external genitalia. *J Trauma*, 1998. 44: 492.
<http://www.ncbi.nlm.nih.gov/pubmed/9529176>

26. Centers for Disease Control and Prevention, Tetanus wound management. <https://www.cdc.gov/vaccines/pubs/pinkbook/downloads/tetanus.pdf>
27. McAninch, J.W. Genitourinary trauma. *World J Urol*, 1999. 17: 65. <http://www.ncbi.nlm.nih.gov/pubmed/10367362>
28. Wessells, H., *et al.* Renal injury and operative management in the United States: results of a population-based study. *J Trauma*, 2003. 54: 423. <http://www.ncbi.nlm.nih.gov/pubmed/12634519>
29. Hurtuk, M., *et al.* Trauma surgeons practice what they preach: The NTDB story on solid organ injury management. *J Trauma*, 2006. 61: 243. <http://www.ncbi.nlm.nih.gov/pubmed/16917435>
30. Santucci, R.A., *et al.* The literature increasingly supports expectant (conservative) management of renal trauma--a systematic review. *J Trauma*, 2005. 59: 493. <http://www.ncbi.nlm.nih.gov/pubmed/16294101>
31. Santucci, R.A., *et al.* Evaluation and management of renal injuries: consensus statement of the renal trauma subcommittee. *BJU Int*, 2004. 93: 937. <http://www.ncbi.nlm.nih.gov/pubmed/15142141>
32. Sangthong, B., *et al.* Management and hospital outcomes of blunt renal artery injuries: analysis of 517 patients from the National Trauma Data Bank. *J Am Coll Surg*, 2006. 203: 612. <http://www.ncbi.nlm.nih.gov/pubmed/17084321>
33. Kansas, B.T., *et al.* Incidence and management of penetrating renal trauma in patients with multiorgan injury: extended experience at an inner city trauma center. *J Urol*, 2004. 172: 1355. <http://www.ncbi.nlm.nih.gov/pubmed/15371841>
34. Najibi, S., *et al.* Civilian gunshot wounds to the genitourinary tract: incidence, anatomic distribution, associated injuries, and outcomes. *Urology*, 2010. 76: 977. <http://www.ncbi.nlm.nih.gov/pubmed/20605196>
35. Shariat, S.F., *et al.* Evidence-based validation of the predictive value of the American Association for the Surgery of Trauma kidney injury scale. *J Trauma*, 2007. 62: 933. <http://www.ncbi.nlm.nih.gov/pubmed/17426551>
36. Santucci, R.A., *et al.* Validation of the American Association for the Surgery of Trauma organ injury severity scale for the kidney. *J Trauma*, 2001. 50: 195. <http://www.ncbi.nlm.nih.gov/pubmed/11242281>
37. Cachecho, R., *et al.* Management of the trauma patient with pre-existing renal disease. *Crit Care Clin*, 1994. 10: 523. <http://www.ncbi.nlm.nih.gov/pubmed/792273629>
38. Cozar, J.M., *et al.* [Management of injury of the solitary kidney]. *Arch Esp Urol*, 1990. 43: 15. <http://www.ncbi.nlm.nih.gov/pubmed/2331159>
39. Sebastia, M.C., *et al.* Renal trauma in occult ureteropelvic junction obstruction: CT findings. *Eur Radiol*, 1999. 9: 611. <http://www.ncbi.nlm.nih.gov/pubmed/10354870>
40. Buchberger, W., *et al.* [Diagnosis and staging of blunt kidney trauma. A comparison of urinalysis, i.v. urography, sonography and computed tomography]. *Rofo*, 1993. 158: 507. <http://www.ncbi.nlm.nih.gov/pubmed/8507839>
41. Carroll, P.R., *et al.* Renovascular trauma: risk assessment, surgical management, and outcome. *J Trauma*, 1990. 30: 547. <http://www.ncbi.nlm.nih.gov/pubmed/2342137>
42. Eastham, J.A., *et al.* Radiographic evaluation of adult patients with blunt renal trauma. *J Urol*, 1992. 148: 266. <http://www.ncbi.nlm.nih.gov/pubmed/1635113>
43. Schmidlin, F.R., *et al.* The higher injury risk of abnormal kidneys in blunt renal trauma. *Scand J Urol Nephrol*, 1998. 32: 388. <http://www.ncbi.nlm.nih.gov/pubmed/9925001>
44. Chandhoke, P.S., *et al.* Detection and significance of microscopic hematuria in patients with blunt renal trauma. *J Urol*, 1988. 140: 16. <http://www.ncbi.nlm.nih.gov/pubmed/3379684>
45. Heyns, C.F. Renal trauma: indications for imaging and surgical exploration. *BJU Int*, 2004. 93: 1165. <http://www.ncbi.nlm.nih.gov/pubmed/15142132>
46. Sheth S, C.D., Remer EM *et al.* ACR Appropriateness Criteria® renal trauma. 2012. <https://acsearch.acr.org/docs/69373/Narrative/>
47. Morey, A.F., *et al.* Urotrauma: AUA guideline. *J Urol*, 2014. 192: 327. <http://www.ncbi.nlm.nih.gov/pubmed/24857651>

48. McCombie, S.P., *et al.* The conservative management of renal trauma: a literature review and practical clinical guideline from Australia and New Zealand. *BJU Int*, 2014. 114 Suppl 1: 13.
<http://www.ncbi.nlm.nih.gov/pubmed/25124459>
49. Poletti, P.A., *et al.* Blunt abdominal trauma: does the use of a second-generation sonographic contrast agent help to detect solid organ injuries? *AJR Am J Roentgenol*, 2004. 183: 1293.
<http://www.ncbi.nlm.nih.gov/pubmed/15505293>
50. Valentino, M., *et al.* Blunt abdominal trauma: emergency contrast-enhanced sonography for detection of solid organ injuries. *AJR Am J Roentgenol*, 2006. 186: 1361.
<http://www.ncbi.nlm.nih.gov/pubmed/16632732>
51. Korner, M., *et al.* Current Role of Emergency US in Patients with Major Trauma. *Radiographics*, 2008. 28: 225.
<http://www.ncbi.nlm.nih.gov/pubmed/18203940>
52. Regine, G., *et al.* Second-generation sonographic contrast agents in the evaluation of renal trauma. *Radiol Med*, 2007. 112: 581.
<http://www.ncbi.nlm.nih.gov/pubmed/17563847>
53. Valentino, M., *et al.* Contrast-enhanced US evaluation in patients with blunt abdominal trauma(). *J Ultrasound*, 2010. 13: 22.
<http://www.ncbi.nlm.nih.gov/pubmed/23396012>
54. Mihalik, J.E., *et al.* The use of contrast-enhanced ultrasound for the evaluation of solid abdominal organ injury in patients with blunt abdominal trauma. *J Trauma Acute Care Surg*, 2012. 73: 1100.
<http://www.ncbi.nlm.nih.gov/pubmed/22832765>
55. Cagini, L., *et al.* Contrast enhanced ultrasound (CEUS) in blunt abdominal trauma. *Crit Ultrasound J*, 2013. 5 Suppl 1: S9.
<http://www.ncbi.nlm.nih.gov/pubmed/23902930>
56. Heller, M.T., *et al.* MDCT of renal trauma: correlation to AAST organ injury scale. *Clin Imaging*, 2014. 38: 410.
<http://www.ncbi.nlm.nih.gov/pubmed/24667041>
57. Huber-Wagner, S., *et al.* Effect of whole-body CT during trauma resuscitation on survival: a retrospective, multicentre study. *Lancet*, 2009. 373: 1455.
<http://www.ncbi.nlm.nih.gov/pubmed/19321199>
58. Alonso, R.C., *et al.* Kidney in danger: CT findings of blunt and penetrating renal trauma. *Radiographics*, 2009. 29: 2033.
<http://www.ncbi.nlm.nih.gov/pubmed/19926761>
59. Colling, K.P., *et al.* Computed tomography scans with intravenous contrast: low incidence of contrast-induced nephropathy in blunt trauma patients. *J Trauma Acute Care Surg*, 2014. 77: 226.
<http://www.ncbi.nlm.nih.gov/pubmed/25058246>
60. Fischer, W., *et al.* JOURNAL CLUB: Incidence of Urinary Leak and Diagnostic Yield of Excretory Phase CT in the Setting of Renal Trauma. *AJR Am J Roentgenol*, 2015. 204: 1168.
<http://www.ncbi.nlm.nih.gov/pubmed/26001225>
61. Morey, A.F., *et al.* Single shot intraoperative excretory urography for the immediate evaluation of renal trauma. *J Urol*, 1999. 161: 1088.
<http://www.ncbi.nlm.nih.gov/pubmed/10081844>
62. Ku, J.H., *et al.* Is there a role for magnetic resonance imaging in renal trauma? *Int J Urol*, 2001. 8: 261.
<http://www.ncbi.nlm.nih.gov/pubmed/11389740>
63. Leppaniemi, A., *et al.* MRI and CT in blunt renal trauma: an update. *Semin Ultrasound CT MR*, 1997. 18: 129.
<http://www.ncbi.nlm.nih.gov/pubmed/9163832>
64. Schmidlin, F.R., *et al.* [The conservative treatment of major kidney injuries]. *Ann Urol (Paris)*, 1997. 31: 246.
<http://www.ncbi.nlm.nih.gov/pubmed/9480627>
65. Holmes, J.F., *et al.* Rate of intra-abdominal injury after a normal abdominal computed tomographic scan in adults with blunt trauma. *Am J Emerg Med*, 2012. 30: 574.
<http://www.ncbi.nlm.nih.gov/pubmed/21641163>
66. Thall, E.H., *et al.* Conservative management of penetrating and blunt Type III renal injuries. *Br J Urol*, 1996. 77: 512.
<http://www.ncbi.nlm.nih.gov/pubmed/8777609>
67. Alsikafi, N.F., *et al.* Nonoperative management outcomes of isolated urinary extravasation following renal lacerations due to external trauma. *J Urol*, 2006. 176: 2494.
<http://www.ncbi.nlm.nih.gov/pubmed/17085140>

68. Buckley, J.C., *et al.* Selective management of isolated and nonisolated grade IV renal injuries. *J Urol*, 2006. 176: 2498.
<http://www.ncbi.nlm.nih.gov/pubmed/17085141>
69. Santucci, R.A., *et al.* Grade IV renal injuries: evaluation, treatment, and outcome. *World J Surg*, 2001. 25: 1565.
<http://www.ncbi.nlm.nih.gov/pubmed/11775193>
70. Altman, A.L., *et al.* Selective nonoperative management of blunt grade 5 renal injury. *J Urol*, 2000. 164: 27.
<http://www.ncbi.nlm.nih.gov/pubmed/10840417>
71. Moudouni, S.M., *et al.* Management of major blunt renal lacerations: is a nonoperative approach indicated? *Eur Urol*, 2001. 40: 409.
<http://www.ncbi.nlm.nih.gov/pubmed/11713395>
72. Husmann, D.A., *et al.* Attempted nonoperative management of blunt renal lacerations extending through the corticomedullary junction: the short-term and long-term sequelae. *J Urol*, 1990. 143: 682.
<http://www.ncbi.nlm.nih.gov/pubmed/2313792>
73. Elliott, S.P., *et al.* Renal arterial injuries: a single center analysis of management strategies and outcomes. *J Urol*, 2007. 178: 2451.
<http://www.ncbi.nlm.nih.gov/pubmed/17937955>
74. Jawas, A., *et al.* Management algorithm for complete blunt renal artery occlusion in multiple trauma patients: case series. *Int J Surg*, 2008. 6: 317.
<http://www.ncbi.nlm.nih.gov/pubmed/18590988>
75. Armenakas, N.A., *et al.* Indications for nonoperative management of renal stab wounds. *J Urol*, 1999. 161: 768.
<http://www.ncbi.nlm.nih.gov/pubmed/10022681>
76. Jansen, J.O., *et al.* Selective non-operative management of abdominal gunshot wounds: survey of practise. *Injury*, 2013. 44: 639.
<http://www.ncbi.nlm.nih.gov/pubmed/22341771>
77. Bernath, A.S., *et al.* Stab wounds of the kidney: conservative management in flank penetration. *J Urol*, 1983. 129: 468.
<http://www.ncbi.nlm.nih.gov/pubmed/6834529>
78. Wessells, H., *et al.* Criteria for nonoperative treatment of significant penetrating renal lacerations. *J Urol*, 1997. 157: 24.
<http://www.ncbi.nlm.nih.gov/pubmed/8976207>
79. Velmahos, G.C., *et al.* Selective management of renal gunshot wounds. *Br J Surg*, 1998. 85: 1121.
<http://www.ncbi.nlm.nih.gov/pubmed/9718011>
80. Baniel, J., *et al.* The management of penetrating trauma to the urinary tract. *J Am Coll Surg*, 1994. 178: 417.
<http://www.ncbi.nlm.nih.gov/pubmed/8149045>
81. DuBose, J., *et al.* Selective non-operative management of solid organ injury following abdominal gunshot wounds. *Injury*, 2007. 38: 1084.
<http://www.ncbi.nlm.nih.gov/pubmed/17544428>
82. Shefler, A., *et al.* [The role of nonoperative management of penetrating renal trauma]. *Harefuah*, 2007. 146: 345.
<http://www.ncbi.nlm.nih.gov/pubmed/17674549>
83. Hope, W.W., *et al.* Non-operative management in penetrating abdominal trauma: is it feasible at a Level II trauma center? *J Emerg Med*, 2012. 43: 190.
<http://www.ncbi.nlm.nih.gov/pubmed/22051843>
84. Lanchon, C., *et al.* High Grade Blunt Renal Trauma: Predictors of Surgery and Long-Term Outcomes of Conservative Management. A Prospective Single Center Study. *J Urol*, 2016. 195: 106.
<http://www.ncbi.nlm.nih.gov/pubmed/26254724>
85. Shoobridge, J.J., *et al.* A 9-year experience of renal injury at an Australian level 1 trauma centre. *BJU Int*, 2013. 112 Suppl 2: 53.
<http://www.ncbi.nlm.nih.gov/pubmed/23418742>
86. van der Wilden, G.M., *et al.* Successful nonoperative management of the most severe blunt renal injuries: a multicenter study of the research consortium of New England Centers for Trauma. *JAMA Surg*, 2013. 148: 924.
<http://www.ncbi.nlm.nih.gov/pubmed/23945834>

87. Charbit, J., *et al.* What are the specific computed tomography scan criteria that can predict or exclude the need for renal angioembolization after high-grade renal trauma in a conservative management strategy? *J Trauma*, 2011. 70: 1219.
<http://www.ncbi.nlm.nih.gov/pubmed/23945834>
88. Lin, W.C., *et al.* Computed tomographic imaging in determining the need of embolization for high-grade blunt renal injury. *J Trauma Acute Care Surg*, 2013. 74: 230.
<http://www.ncbi.nlm.nih.gov/pubmed/23271099>
89. Huber, J., *et al.* Selective transarterial embolization for posttraumatic renal hemorrhage: a second try is worthwhile. *J Urol*, 2011. 185: 1751.
<http://www.ncbi.nlm.nih.gov/pubmed/21420122>
90. Hotaling, J.M., *et al.* Analysis of diagnostic angiography and angioembolization in the acute management of renal trauma using a national data set. *J Urol*, 2011. 185: 1316.
<http://www.ncbi.nlm.nih.gov/pubmed/21334643>
91. Saour, M., *et al.* Effect of renal angioembolization on post-traumatic acute kidney injury after high-grade renal trauma: a comparative study of 52 consecutive cases. *Injury*, 2014. 45: 894.
<http://www.ncbi.nlm.nih.gov/pubmed/24456608>
92. Moolman, C., *et al.* Nonoperative management of penetrating kidney injuries: a prospective audit. *J Urol*, 2012. 188: 169.
<http://www.ncbi.nlm.nih.gov/pubmed/22591960>
93. Bjurlin, M.A., *et al.* Comparison of nonoperative management with renorrhaphy and nephrectomy in penetrating renal injuries. *J Trauma*, 2011. 71: 554.
<http://www.ncbi.nlm.nih.gov/pubmed/21610541>
94. Glass, A.S., *et al.* Selective angioembolization for traumatic renal injuries: a survey on clinician practice. *World J Urol*, 2014. 32: 821.
<http://www.ncbi.nlm.nih.gov/pubmed/24072011>
95. Husmann, D.A., *et al.* Major renal lacerations with a devitalized fragment following blunt abdominal trauma: a comparison between nonoperative (expectant) versus surgical management. *J Urol*, 1993. 150: 1774.
<http://www.ncbi.nlm.nih.gov/pubmed/24072011>
96. McAninch, J.W., *et al.* Renal reconstruction after injury. *J Urol*, 1991. 145: 932.
<https://www.ncbi.nlm.nih.gov/pubmed/2016804>
97. Hotaling, J.M., *et al.* A national study of trauma level designation and renal trauma outcomes. *J Urol*, 2012. 187: 536.
<http://www.ncbi.nlm.nih.gov/pubmed/22177171>
98. Broghammer, J.A., *et al.* Conservative management of renal trauma: a review. *Urology*, 2007. 70: 623.
<http://www.ncbi.nlm.nih.gov/pubmed/17991526>
99. Sartorelli, K.H., *et al.* Nonoperative management of hepatic, splenic, and renal injuries in adults with multiple injuries. *J Trauma*, 2000. 49: 56.
<http://www.ncbi.nlm.nih.gov/pubmed/10912858>
100. Toutouzas, K.G., *et al.* Nonoperative management of blunt renal trauma: a prospective study. *Am Surg*, 2002. 68: 1097.
<http://www.ncbi.nlm.nih.gov/pubmed/12516817>
101. Dugi, D.D., 3rd, *et al.* American Association for the Surgery of Trauma grade 4 renal injury substratification into grades 4a (low risk) and 4b (high risk). *J Urol*, 2010. 183: 592.
<http://www.ncbi.nlm.nih.gov/pubmed/20018329>
102. Hammer, C.C., *et al.* Effect of an institutional policy of nonoperative treatment of grades I to IV renal injuries. *J Urol*, 2003. 169: 1751.
<http://www.ncbi.nlm.nih.gov/pubmed/12686825>
103. Robert, M., *et al.* Management of major blunt renal lacerations: surgical or nonoperative approach? *Eur Urol*, 1996. 30: 335.
<http://www.ncbi.nlm.nih.gov/pubmed/8931966>
104. Nash, P.A., *et al.* Nephrectomy for traumatic renal injuries. *J Urol*, 1995. 153: 609.
<http://www.ncbi.nlm.nih.gov/pubmed/7861494>
105. Gonzalez, R.P., *et al.* Surgical management of renal trauma: is vascular control necessary? *J Trauma*, 1999. 47: 1039.
<http://www.ncbi.nlm.nih.gov/pubmed/10608530>
106. Rostas, J., *et al.* Intraoperative management of renal gunshot injuries: is mandatory exploration of Gerota's fascia necessary? *Am J Surg*, 2016. 211: 783.
<http://www.ncbi.nlm.nih.gov/pubmed/26867480>

107. Atala, A., *et al.* Preliminary vascular control for renal trauma. *Surg Gynecol Obstet*, 1991. 172: 386.
<http://www.ncbi.nlm.nih.gov/pubmed/2028374>
108. Chaabouni, M.N., *et al.* [Application of a peri-renal prosthesis (vicryl mesh) in the conservative treatment of multiple ruptured kidney fragments]. *Ann Urol (Paris)*, 1996. 30: 61.
<http://www.ncbi.nlm.nih.gov/pubmed/8767808>
109. Master, V.A., *et al.* Operative management of renal injuries: parenchymal and vascular. *Urol Clin North Am*, 2006. 33: 21.
<http://www.ncbi.nlm.nih.gov/pubmed/16488277>
110. Davis, K.A., *et al.* Predictors of the need for nephrectomy after renal trauma. *J Trauma*, 2006. 60: 164.
<http://www.ncbi.nlm.nih.gov/pubmed/16456451>
111. Wright, J.L., *et al.* Renal and extrarenal predictors of nephrectomy from the national trauma data bank. *J Urol*, 2006. 175: 970.
<http://www.ncbi.nlm.nih.gov/pubmed/16469594>
112. DiGiacomo, J.C., *et al.* The role of nephrectomy in the acutely injured. *Arch Surg*, 2001. 136: 1045.
<http://www.ncbi.nlm.nih.gov/pubmed/11529828>
113. Brandes, S.B., *et al.* Reconstructive surgery for trauma of the upper urinary tract. *Urol Clin North Am*, 1999. 26: 183.
<http://www.ncbi.nlm.nih.gov/pubmed/10086060>
114. McAninch, J.W., *et al.* [The surgical treatment of renal trauma]. *Vestn Khir Im I I Grek*, 1990. 145: 64.
<http://www.ncbi.nlm.nih.gov/pubmed/1966179>
115. Shekarriz, B., *et al.* The use of fibrin sealant in urology. *J Urol*, 2002. 167: 1218.
<http://www.ncbi.nlm.nih.gov/pubmed/11832701>
116. Knudson, M.M., *et al.* Outcome after major renovascular injuries: a Western trauma association multicenter report. *J Trauma*, 2000. 49: 1116.
<http://www.ncbi.nlm.nih.gov/pubmed/11130498>
117. Tillou, A., *et al.* Renal vascular injuries. *Surg Clin North Am*, 2001. 81: 1417.
<http://www.ncbi.nlm.nih.gov/pubmed/11766183>
118. Blankenship, J.C., *et al.* Importance of delayed imaging for blunt renal trauma. *World J Surg*, 2001. 25: 1561.
<http://www.ncbi.nlm.nih.gov/pubmed/11775192>
119. McGuire, J., *et al.* Predictors of outcome for blunt high grade renal injury treated with conservative intent. *J Urol*, 2011. 185: 187.
<http://www.ncbi.nlm.nih.gov/pubmed/21074795>
120. Wessells, H., *et al.* Preservation of renal function after reconstruction for trauma: quantitative assessment with radionuclide scintigraphy. *J Urol*, 1997. 157: 1583.
<http://www.ncbi.nlm.nih.gov/pubmed/9112481>
121. Tasian, G.E., *et al.* Evaluation of renal function after major renal injury: correlation with the American Association for the Surgery of Trauma Injury Scale. *J Urol*, 2010. 183: 196.
<http://www.ncbi.nlm.nih.gov/pubmed/19913819>
122. Fiard, G., *et al.* Long-term renal function assessment with dimercapto-succinic acid scintigraphy after conservative treatment of major renal trauma. *J Urol*, 2012. 187: 1306.
<http://www.ncbi.nlm.nih.gov/pubmed/22341289>
123. Dunfee, B.L., *et al.* Development of renal scars on CT after abdominal trauma: does grade of injury matter? *AJR Am J Roentgenol*, 2008. 190: 1174.
<http://www.ncbi.nlm.nih.gov/pubmed/18430828>
124. Heyns, C.F., *et al.* Increasing role of angiography and segmental artery embolization in the management of renal stab wounds. *J Urol*, 1992. 147: 1231.
<http://www.ncbi.nlm.nih.gov/pubmed/1569655>
125. Monstrey, S.J., *et al.* Renal trauma and hypertension. *J Trauma*, 1989. 29: 65.
<http://www.ncbi.nlm.nih.gov/pubmed/2911106>
126. Lebech, A., *et al.* [Hypertension following blunt kidney injury]. *Ugeskr Laeger*, 1990. 152: 994.
<http://www.ncbi.nlm.nih.gov/pubmed/2183457>
127. Montgomery, R.C., *et al.* Posttraumatic renovascular hypertension after occult renal injury. *J Trauma*, 1998. 45: 106.
<http://www.ncbi.nlm.nih.gov/pubmed/9680021>
128. Haas, C.A., *et al.* Use of ureteral stents in the management of major renal trauma with urinary extravasation: is there a role? *J Endourol*, 1998. 12: 545.
<http://www.ncbi.nlm.nih.gov/pubmed/9895260>

129. Matthews, L.A., *et al.* Nonoperative treatment of major blunt renal lacerations with urinary extravasation. *J Urol*, 1997. 157: 2056.
<http://www.ncbi.nlm.nih.gov/pubmed/9146579>
130. Wang, K.T., *et al.* Late development of renal arteriovenous fistula following gunshot trauma--a case report. *Angiology*, 1998. 49: 415.
<http://www.ncbi.nlm.nih.gov/pubmed/9591535>
131. Salazar, G.M., *et al.* Evaluation and management of acute vascular trauma. *Tech Vasc Interv Radiol*, 2009. 12: 102.
<http://www.ncbi.nlm.nih.gov/pubmed/19853228>
132. Miller, D.C., *et al.* Successful angioembolization of renal artery pseudoaneurysms after blunt abdominal trauma. *Urology*, 2002. 59: 444.
<http://www.ncbi.nlm.nih.gov/pubmed/11880095>
133. Harrington, T.G., *et al.* Renal colic following a gunshot wound to the abdomen: the birdshot calculus. *J Urol*, 1997. 157: 1351.
<http://www.ncbi.nlm.nih.gov/pubmed/9120940>
134. Heye, S., *et al.* Iatrogenic main renal artery injury: treatment by endovascular stent-graft placement. *Cardiovasc Intervent Radiol*, 2005. 28: 93.
<http://www.ncbi.nlm.nih.gov/pubmed/15602634>
135. Maleux, G., *et al.* Transcatheter embolization of biopsy-related vascular injuries in renal allografts. Long-term technical, clinical and biochemical results. *Acta Radiol*, 2003. 44: 13.
<http://www.ncbi.nlm.nih.gov/pubmed/12630992>
136. Albani, J.M., *et al.* Renal artery pseudoaneurysm after partial nephrectomy: three case reports and a literature review. *Urology*, 2003. 62: 227.
<http://www.ncbi.nlm.nih.gov/pubmed/12893324>
137. Furness, P.N., *et al.* Protocol biopsy of the stable renal transplant: a multicenter study of methods and complication rates. *Transplantation*, 2003. 76: 969.
<http://www.ncbi.nlm.nih.gov/pubmed/14508363>
138. Barley, F.L., *et al.* Selective embolization of large symptomatic iatrogenic renal transplant arteriovenous fistula. *Cardiovasc Intervent Radiol*, 2006. 29: 1084.
<http://www.ncbi.nlm.nih.gov/pubmed/16794894>
139. Takahashi, M., *et al.* Early posttransplantation renal allograft perfusion failure due to dissection: diagnosis and interventional treatment. *AJR Am J Roentgenol*, 2003. 180: 759.
<http://www.ncbi.nlm.nih.gov/pubmed/12591692>
140. Bellman, G.C. Complications of endopyelotomy. *J Endourol*, 1996. 10: 177.
<http://www.ncbi.nlm.nih.gov/pubmed/8728685>
141. Hinshaw, J.L., *et al.* Comparison of percutaneous and laparoscopic cryoablation for the treatment of solid renal masses. *AJR Am J Roentgenol*, 2008. 191: 1159.
<http://www.ncbi.nlm.nih.gov/pubmed/18806159>
142. Phadke, R.V., *et al.* Iatrogenic renal vascular injuries and their radiological management. *Clin Radiol*, 1997. 52: 119.
<http://www.ncbi.nlm.nih.gov/pubmed/043045>
143. Cohenpour, M., *et al.* Pseudoaneurysm of the renal artery following partial nephrectomy: imaging findings and coil embolization. *Clin Radiol*, 2007. 62: 1104.
<http://www.ncbi.nlm.nih.gov/pubmed/17920871>
144. Loffroy, R., *et al.* Management of post-biopsy renal allograft arteriovenous fistulas with selective arterial embolization: immediate and long-term outcomes. *Clin Radiol*, 2008. 63: 657.
<http://www.ncbi.nlm.nih.gov/pubmed/18455557>
145. Ben Meir, D., *et al.* Intrarenal foreign body presenting as a solid tumor. *Urology*, 2003. 61: 1035.
<http://www.ncbi.nlm.nih.gov/pubmed/12736036>
146. Nakada, S.Y., *et al.* Ureteropelvic junction obstruction. Retrograde endopyelotomy. *Urol Clin North Am*, 2000. 27: 677.
<http://www.ncbi.nlm.nih.gov/pubmed/11098766>
147. Jones, C.D., *et al.* Computed tomographic evaluation and guided correction of malpositioned nephrostomy catheters. *Abdom Imaging*, 1999. 24: 422.
<http://www.ncbi.nlm.nih.gov/pubmed/10390572>
148. Silberzweig, J.E., *et al.* Percutaneous renal biopsy complicated by renal capsular artery pseudoaneurysm. *Am J Kidney Dis*, 1998. 31: 533.
<http://www.ncbi.nlm.nih.gov/pubmed/9506693>

149. Gupta, M., *et al.* Massive hemorrhage from renal vein injury during percutaneous renal surgery: endourological management. *J Urol*, 1997. 157: 795.
<http://www.ncbi.nlm.nih.gov/pubmed/9072568>
150. El-Nahas, A.R., *et al.* Post-percutaneous nephrolithotomy extensive hemorrhage: a study of risk factors. *J Urol*, 2007. 177: 576.
<http://www.ncbi.nlm.nih.gov/pubmed/17222636>
151. El-Nahas, A.R., *et al.* Functional and morphological effects of postpercutaneous nephrolithotomy superselective renal angiographic embolization. *Urology*, 2008. 71: 408.
<http://www.ncbi.nlm.nih.gov/pubmed/18342174>
152. Ghai, B., *et al.* Massive intraabdominal extravasation of fluid: a life threatening complication following percutaneous nephrolithotomy. *Int Urol Nephrol*, 2003. 35: 315.
<http://www.ncbi.nlm.nih.gov/pubmed/15160530>
153. Oderich, G.S., *et al.* Iatrogenic operative injuries of abdominal and pelvic veins: a potentially lethal complication. *J Vasc Surg*, 2004. 39: 931.
<http://www.ncbi.nlm.nih.gov/pubmed/15111840>
154. Taneja, M., *et al.* Renal vascular injuries following nephron-sparing surgery and their endovascular management. *Singapore Med J*, 2008. 49: 63.
<http://www.ncbi.nlm.nih.gov/pubmed/18204772>
155. Inci, K., *et al.* Renal artery pseudoaneurysm: complication of minimally invasive kidney surgery. *J Endourol*, 2010. 24: 149.
<http://www.ncbi.nlm.nih.gov/pubmed/19954351>
156. Perini, S., *et al.* Transcatheter embolization of biopsy-related vascular injury in the transplant kidney: immediate and long-term outcome. *J Vasc Interv Radiol*, 1998. 9: 1011.
<http://www.ncbi.nlm.nih.gov/pubmed/9840051>
157. Nakatani, T., *et al.* Renal allograft arteriovenous fistula and large pseudoaneurysm. *Clin Transplant*, 2003. 17: 9.
<http://www.ncbi.nlm.nih.gov/pubmed/12588315>
158. Breyer, B.N., *et al.* Minimally invasive endovascular techniques to treat acute renal hemorrhage. *J Urol*, 2008. 179: 2248.
<http://www.ncbi.nlm.nih.gov/pubmed/18423679>
159. Wang, M.Q., *et al.* [Treatment of acquired arteriovenous fistulas with interventional minimally invasive techniques]. *Zhonghua Wai Ke Za Zhi*, 2004. 42: 687.
<http://www.ncbi.nlm.nih.gov/pubmed/15329261>
160. Morris, C.S., *et al.* Nonsurgical treatment of acute iatrogenic renal artery injuries occurring after renal artery angioplasty and stenting. *AJR Am J Roentgenol*, 2001. 177: 1353.
<http://www.ncbi.nlm.nih.gov/pubmed/11717082>
161. Elliott, S.P., *et al.* Ureteral injuries: external and iatrogenic. *Urol Clin North Am*, 2006. 33: 55.
<http://www.ncbi.nlm.nih.gov/pubmed/16488280>
162. McGeady, J.B., *et al.* Current epidemiology of genitourinary trauma. *Urol Clin North Am*, 2013. 40: 323.
<http://www.ncbi.nlm.nih.gov/pubmed/23905930>
163. Siram, S.M., *et al.* Ureteral trauma: patterns and mechanisms of injury of an uncommon condition. *Am J Surg*, 2010. 199: 566.
<http://www.ncbi.nlm.nih.gov/pubmed/20359576>
164. Serkin, F.B., *et al.* Combat urologic trauma in US military overseas contingency operations. *J Trauma*, 2010. 69 Suppl 1: S175.
<http://www.ncbi.nlm.nih.gov/pubmed/20622614>
165. Brandes, S., *et al.* Diagnosis and management of ureteric injury: an evidence-based analysis. *BJU Int*, 2004. 94: 277.
<http://www.ncbi.nlm.nih.gov/pubmed/15291852>
166. Chou, M.T., *et al.* Prophylactic ureteral catheterization in gynecologic surgery: a 12-year randomized trial in a community hospital. *Int Urogynecol J Pelvic Floor Dysfunct*, 2009. 20: 689.
<http://www.ncbi.nlm.nih.gov/pubmed/19165412>
167. Delacroix, S.E., Jr., *et al.* Urinary tract injuries: recognition and management. *Clin Colon Rectal Surg*, 2010. 23: 104.
<http://www.ncbi.nlm.nih.gov/pubmed/21629628>
168. Visco, A.G., *et al.* Cost-effectiveness of universal cystoscopy to identify ureteral injury at hysterectomy. *Obstet Gynecol*, 2001. 97: 685.
<http://www.ncbi.nlm.nih.gov/pubmed/11339916>

169. Halabi, W.J., *et al.* Ureteral injuries in colorectal surgery: an analysis of trends, outcomes, and risk factors over a 10-year period in the United States. *Dis Colon Rectum*, 2014. 57: 179.
<http://www.ncbi.nlm.nih.gov/pubmed/24401879>
170. Johnson, D.B., *et al.* Complications of ureteroscopy. *Urol Clin North Am*, 2004. 31: 157.
<http://www.ncbi.nlm.nih.gov/pubmed/15040412>
171. Schimpf, M.O., *et al.* Universal ureteral stent placement at hysterectomy to identify ureteral injury: a decision analysis. *BJOG*, 2008. 115: 1151.
<http://www.ncbi.nlm.nih.gov/pubmed/18518875>
172. Gilmour, D.T., *et al.* Rates of urinary tract injury from gynecologic surgery and the role of intraoperative cystoscopy. *Obstet Gynecol*, 2006. 107: 1366.
<http://www.ncbi.nlm.nih.gov/pubmed/16738165>
173. Wu, H.H., *et al.* The detection of ureteral injuries after hysterectomy. *J Minim Invasive Gynecol*, 2006. 13: 403.
<http://www.ncbi.nlm.nih.gov/pubmed/16962522>
174. Pokala, N., *et al.* A randomized controlled trial comparing simultaneous intra-operative vs sequential prophylactic ureteric catheter insertion in re-operative and complicated colorectal surgery. *Int J Colorectal Dis*, 2007. 22: 683.
<http://www.ncbi.nlm.nih.gov/pubmed/17031654>
175. Jhaveri, J.K., *et al.* Ureteral injuries sustained during robot-assisted radical prostatectomy. *J Endourol*, 2014. 28: 318.
<http://www.ncbi.nlm.nih.gov/pubmed/24147874>
176. Kunkle, D.A., *et al.* Delayed diagnosis of traumatic ureteral injuries. *J Urol*, 2006. 176: 2503.
<http://www.ncbi.nlm.nih.gov/pubmed/17085143>
177. Parpala-Sparman, T., *et al.* Increasing numbers of ureteric injuries after the introduction of laparoscopic surgery. *Scand J Urol Nephrol*, 2008. 42: 422.
<http://www.ncbi.nlm.nih.gov/pubmed/18609278>
178. Medina, D., *et al.* Ureteral trauma: preoperative studies neither predict injury nor prevent missed injuries. *J Am Coll Surg*, 1998. 186: 641.
<http://www.ncbi.nlm.nih.gov/pubmed/9632150>
179. Lucarelli, G., *et al.* Delayed relief of ureteral obstruction is implicated in the long-term development of renal damage and arterial hypertension in patients with unilateral ureteral injury. *J Urol*, 2013. 189: 960.
<http://www.ncbi.nlm.nih.gov/pubmed/23017525>
180. Speicher, P.J., *et al.* Ureteral stenting in laparoscopic colorectal surgery. *J Surg Res*, 2014. 190: 98.
<http://www.ncbi.nlm.nih.gov/pubmed/24656474>
181. Smith, T.G., 3rd, *et al.* Damage control maneuvers for urologic trauma. *Urol Clin North Am*, 2013. 40: 343.
<http://www.ncbi.nlm.nih.gov/pubmed/23905932>
182. Koukouras, D., *et al.* Percutaneous minimally invasive management of iatrogenic ureteral injuries. *J Endourol*, 2010. 24: 1921.
<http://www.ncbi.nlm.nih.gov/pubmed/20964484>
183. El Abd, A.S., *et al.* Immediate and late management of iatrogenic ureteric injuries: 28 years of experience. *Arab J Urol*, 2015. 13: 250.
<http://www.ncbi.nlm.nih.gov/pubmed/26609443>
184. Png, J.C., *et al.* Principles of ureteric reconstruction. *Curr Opin Urol*, 2000. 10: 207.
<http://www.ncbi.nlm.nih.gov/pubmed/10858898>
185. Burks, F.N., *et al.* Management of iatrogenic ureteral injury. *Ther Adv Urol*, 2014. 6: 115.
<http://www.ncbi.nlm.nih.gov/pubmed/24883109>
186. Wenske, S., *et al.* Outcomes of distal ureteral reconstruction through reimplantation with psoas hitch, Boari flap, or ureteroneocystostomy for benign or malignant ureteral obstruction or injury. *Urology*, 2013. 82: 231.
<http://www.ncbi.nlm.nih.gov/pubmed/23642933>
187. Chung, B.I., *et al.* The use of bowel for ureteral replacement for complex ureteral reconstruction: long-term results. *J Urol*, 2006. 175: 179.
<http://www.ncbi.nlm.nih.gov/pubmed/16406903>
188. Armatys, S.A., *et al.* Use of ileum as ureteral replacement in urological reconstruction. *J Urol*, 2009. 181: 177.
<http://www.ncbi.nlm.nih.gov/pubmed/19013597>

189. Meng, M.V., *et al.* Expanded experience with laparoscopic nephrectomy and autotransplantation for severe ureteral injury. *J Urol*, 2003. 169: 1363.
<http://www.ncbi.nlm.nih.gov/pubmed/12629362>
190. Pereira, B.M., *et al.* Bladder injuries after external trauma: 20 years experience report in a population-based cross-sectional view. *World J Urol*, 2013. 31: 913.
<http://www.ncbi.nlm.nih.gov/pubmed/22544337>
191. Figler, B.D., *et al.* Multi-disciplinary update on pelvic fracture associated bladder and urethral injuries. *Injury*, 2012. 43: 1242.
<http://www.ncbi.nlm.nih.gov/pubmed/22592152>
192. Wirth, G.J., *et al.* Advances in the management of blunt traumatic bladder rupture: experience with 36 cases. *BJU Int*, 2010. 106: 1344.
<http://www.ncbi.nlm.nih.gov/pubmed/20438556>
193. Deibert, C.M., *et al.* The association between operative repair of bladder injury and improved survival: results from the National Trauma Data Bank. *J Urol*, 2011. 186: 151.
<http://www.ncbi.nlm.nih.gov/pubmed/21575961>
194. Matlock, K.A., *et al.* Blunt traumatic bladder rupture: a 10-year perspective. *Am Surg*, 2013. 79: 589.
<http://www.ncbi.nlm.nih.gov/pubmed/23711268>
195. Urry, R.J., *et al.* The incidence, spectrum and outcomes of traumatic bladder injuries within the Pietermaritzburg Metropolitan Trauma Service. *Injury*, 2016. 47: 1057.
<http://www.ncbi.nlm.nih.gov/pubmed/26854075>
196. Johnsen, N.V., *et al.* Evaluating the Role of Operative Repair of Extraperitoneal Bladder Rupture Following Blunt Pelvic Trauma. *J Urol*, 2016. 195: 661.
<http://www.ncbi.nlm.nih.gov/pubmed/26318983>
197. Cinman, N.M., *et al.* Gunshot wounds to the lower urinary tract: a single-institution experience. *J Trauma Acute Care Surg*, 2013. 74: 725.
<http://www.ncbi.nlm.nih.gov/pubmed/23425728>
198. Al-Azzawi, I.S., *et al.* Lower genitourinary trauma in modern warfare: the experience from civil violence in Iraq. *Injury*, 2014. 45: 885.
<http://www.ncbi.nlm.nih.gov/pubmed/24485550>
199. Williams, M., *et al.* Management of combat-related urological trauma in the modern era. *Nat Rev Urol*, 2013. 10: 504.
<http://www.ncbi.nlm.nih.gov/pubmed/23877722>
200. Cordon, B.H., *et al.* Iatrogenic nonendoscopic bladder injuries over 24 years: 127 cases at a single institution. *Urology*, 2014. 84: 222.
<http://www.ncbi.nlm.nih.gov/pubmed/24857278>
201. Tarney, C.M. Bladder Injury During Cesarean Delivery. *Curr Womens Health Rev*, 2013. 9: 70.
<http://www.ncbi.nlm.nih.gov/pubmed/24876830>
202. Shazly, S.A., *et al.* Robotic radical hysterectomy in early stage cervical cancer: A systematic review and meta-analysis. *Gynecol Oncol*, 2015. 138: 457.
<http://www.ncbi.nlm.nih.gov/pubmed/26056752>
203. Brummer, T.H., *et al.* FINHYST, a prospective study of 5279 hysterectomies: complications and their risk factors. *Hum Reprod*, 2011. 26: 1741.
<http://www.ncbi.nlm.nih.gov/pubmed/21540244>
204. Sawkar, H.P., *et al.* Frequency of lower urinary tract injury after gastrointestinal surgery in the nationwide inpatient sample database. *Am Surg*, 2014. 80: 1216.
<http://www.ncbi.nlm.nih.gov/pubmed/25513920>
205. Honore, C., *et al.* HIPEC for peritoneal carcinomatosis: does an associated urologic procedure increase morbidity? *Ann Surg Oncol*, 2012. 19: 104.
<http://www.ncbi.nlm.nih.gov/pubmed/21638092>
206. Kockerling, F., *et al.* TEP versus TAPP: comparison of the perioperative outcome in 17,587 patients with a primary unilateral inguinal hernia. *Surg Endosc*, 2015. 29: 3750.
<http://www.ncbi.nlm.nih.gov/pubmed/25805239>
207. Welk, B.K., *et al.* Are male slings for post-prostatectomy incontinence a valid option? *Curr Opin Urol*, 2010. 20: 465.
<http://www.ncbi.nlm.nih.gov/pubmed/20838219>
208. Maher, C.F., *et al.* Laparoscopic sacral colpopexy versus total vaginal mesh for vaginal vault prolapse: a randomized trial. *Am J Obstet Gynecol*, 2011. 204: 360 e1.
<http://www.ncbi.nlm.nih.gov/pubmed/21306698>

209. Novara, G., *et al.* Updated systematic review and meta-analysis of the comparative data on colposuspensions, pubovaginal slings, and midurethral tapes in the surgical treatment of female stress urinary incontinence. *Eur Urol*, 2010. 58: 218.
<http://www.ncbi.nlm.nih.gov/pubmed/20434257>
210. Ogah, J., *et al.* Minimally invasive synthetic suburethral sling operations for stress urinary incontinence in women: a short version Cochrane review. *Neurourol Urodyn*, 2011. 30: 284.
<http://www.ncbi.nlm.nih.gov/pubmed/21412819>
211. Maher, C., *et al.* Transvaginal mesh or grafts compared with native tissue repair for vaginal prolapse. *Cochrane Database Syst Rev*, 2016. 2: Cd012079.
<http://www.ncbi.nlm.nih.gov/pubmed/26858090>
212. Balbay, M.D., *et al.* The actual incidence of bladder perforation following transurethral bladder surgery. *J Urol*, 2005. 174: 2260.
<http://www.ncbi.nlm.nih.gov/pubmed/16280794>
213. Nieder, A.M., *et al.* Transurethral bladder tumor resection: intraoperative and postoperative complications in a residency setting. *J Urol*, 2005. 174: 2307.
<http://www.ncbi.nlm.nih.gov/pubmed/16280830>
214. Golan, S., *et al.* Transurethral resection of bladder tumour complicated by perforation requiring open surgical repair - clinical characteristics and oncological outcomes. *BJU Int*, 2011. 107: 1065.
<http://www.ncbi.nlm.nih.gov/pubmed/20860654>
215. El Hayek, O.R., *et al.* Evaluation of the incidence of bladder perforation after transurethral bladder tumor resection in a residency setting. *J Endourol*, 2009. 23: 1183.
<http://www.ncbi.nlm.nih.gov/pubmed/19530900>
216. Sugihara, T., *et al.* Comparison of perioperative outcomes including severe bladder injury between monopolar and bipolar transurethral resection of bladder tumors: a population based comparison. *J Urol*, 2014. 192: 1355.
<http://www.ncbi.nlm.nih.gov/pubmed/24893311>
217. Venkatramani, V., *et al.* Monopolar versus bipolar transurethral resection of bladder tumors: a single center, parallel arm, randomized, controlled trial. *J Urol*, 2014. 191: 1703.
<http://www.ncbi.nlm.nih.gov/pubmed/24333244>
218. Collado, A., *et al.* Early complications of endoscopic treatment for superficial bladder tumors. *J Urol*, 2000. 164: 1529.
<http://www.ncbi.nlm.nih.gov/pubmed/11025697>
219. Barber, M.D. Surgical techniques for removing problematic mesh. *Clin Obstet Gynecol*, 2013. 56: 289.
<http://www.ncbi.nlm.nih.gov/pubmed/23563870>
220. Pereira, B.M., *et al.* Penetrating bladder trauma: a high risk factor for associated rectal injury. *Adv Urol*, 2014. 2014: 386280.
<http://www.ncbi.nlm.nih.gov/pubmed/24527030>
221. Clarke-Pearson, D.L., *et al.* Complications of hysterectomy. *Obstet Gynecol*, 2013. 121: 654.
<http://www.ncbi.nlm.nih.gov/pubmed/23635631>
222. Manikandan, R., *et al.* Percutaneous peritoneal drainage for intraperitoneal bladder perforations during transurethral resection of bladder tumors. *J Endourol*, 2003. 17: 945.
<http://www.ncbi.nlm.nih.gov/pubmed/14744369>
223. Patel, B.N., *et al.* Imaging of iatrogenic complications of the urinary tract: kidneys, ureters, and bladder. *Radiol Clin North Am*, 2014. 52: 1101.
<http://www.ncbi.nlm.nih.gov/pubmed/25173661>
224. Frenkl, T.L., *et al.* Management of iatrogenic foreign bodies of the bladder and urethra following pelvic floor surgery. *Neurourol Urodyn*, 2008. 27: 491.
<http://www.ncbi.nlm.nih.gov/pubmed/18537142>
225. MacDonald, S., *et al.* Complications of Transvaginal Mesh for Pelvic Organ Prolapse and Stress Urinary Incontinence: Tips for Prevention, Recognition, and Management. *Eur Urol Focus*, 2016. 2: 260.
<http://www.ncbi.nlm.nih.gov/pubmed/28723371>
226. Lehnert, B.E., *et al.* Lower male genitourinary trauma: a pictorial review. *Emerg Radiol*, 2014. 21: 67.
<http://www.ncbi.nlm.nih.gov/pubmed/24052083>
227. Quagliano, P.V., *et al.* Diagnosis of blunt bladder injury: A prospective comparative study of computed tomography cystography and conventional retrograde cystography. *J Trauma*, 2006. 61: 410.
<http://www.ncbi.nlm.nih.gov/pubmed/16917459>

228. Alperin, M., *et al.* Conservative management of postoperatively diagnosed cystotomy. *Urology*, 2009. 73: 1163 e17.
<http://www.ncbi.nlm.nih.gov/pubmed/18514295>
229. Teeluckdhar, B., *et al.* Urinary Tract Injury at Benign Gynecologic Surgery and the Role of Cystoscopy: A Systematic Review and Meta-analysis. *Obstet Gynecol*, 2015. 126: 1161.
<http://www.ncbi.nlm.nih.gov/pubmed/26551173>
230. Stember, D.S., *et al.* Outcomes of abdominal wall reservoir placement in inflatable penile prosthesis implantation: a safe and efficacious alternative to the space of Retzius. *J Sex Med*, 2014. 11: 605.
<http://www.ncbi.nlm.nih.gov/pubmed/24286533>
231. Oh, J.S., *et al.* Effectiveness of the combat pelvic protection system in the prevention of genital and urinary tract injuries: An observational study. *J Trauma Acute Care Surg*, 2015. 79: S193.
<http://www.ncbi.nlm.nih.gov/pubmed/26406430>
232. Pansadoro, A., *et al.* Conservative treatment of intraperitoneal bladder perforation during transurethral resection of bladder tumor. *Urology*, 2002. 60: 682.
<http://www.ncbi.nlm.nih.gov/pubmed/12385934>
233. Inaba, K., *et al.* Selective nonoperative management of torso gunshot wounds: when is it safe to discharge? *J Trauma*, 2010. 68: 1301.
<http://www.ncbi.nlm.nih.gov/pubmed/22341771>
234. Lee, J.S., *et al.* Urologic complications following obstetric and gynecologic surgery. *Korean J Urol*, 2012. 53: 795.
<http://www.ncbi.nlm.nih.gov/pubmed/23185673>
235. Traxer, O., *et al.* Technique and complications of transurethral surgery for bladder tumours. *BJU Int*, 2004. 94: 492.
<http://www.ncbi.nlm.nih.gov/pubmed/15329099>
236. Rafique, M. Intravesical foreign bodies: review and current management strategies. *Urol J*, 2008. 5: 223.
<http://www.ncbi.nlm.nih.gov/pubmed/19101894>
237. Inaba, K., *et al.* Prospective evaluation of the utility of routine postoperative cystogram after traumatic bladder injury. *J Trauma Acute Care Surg*, 2013. 75: 1019.
<http://www.ncbi.nlm.nih.gov/pubmed/24256676>
238. Mundy, A.R., *et al.* Urethral trauma. Part I: introduction, history, anatomy, pathology, assessment and emergency management. *BJU Int*, 2011. 108: 310.
<http://www.ncbi.nlm.nih.gov/pubmed/19874306>
239. Kashefi, C., *et al.* Incidence and prevention of iatrogenic urethral injuries. *J Urol*, 2008. 179: 2254.
<http://www.ncbi.nlm.nih.gov/pubmed/18423712>
240. Fenton, A.S., *et al.* Anterior urethral strictures: etiology and characteristics. *Urology*, 2005. 65: 1055.
<http://www.ncbi.nlm.nih.gov/pubmed/15913734>
241. Davis, N.F., *et al.* Incidence, Cost, Complications and Clinical Outcomes of Iatrogenic Urethral Catheterization Injuries: A Prospective Multi-Institutional Study. *J Urol*, 2016. 196: 1473.
<http://www.ncbi.nlm.nih.gov/pubmed/27317985>
242. Buddha, S. Complication of urethral catheterisation. *Lancet*, 2005. 365: 909.
<http://www.ncbi.nlm.nih.gov/pubmed/15752537>
243. Hammarsten, J., *et al.* Suprapubic catheter following transurethral resection of the prostate: a way to decrease the number of urethral strictures and improve the outcome of operations. *J Urol*, 1992. 147: 648.
<http://www.ncbi.nlm.nih.gov/pubmed/1538447>
244. Katz, G., *et al.* Prevention of urethral strictures following coronary artery bypass graft surgery. *Urology*, 1992. 39: 433.
<http://www.ncbi.nlm.nih.gov/pubmed/1580032>
245. Thomas, A.Z., *et al.* Avoidable iatrogenic complications of urethral catheterization and inadequate intern training in a tertiary-care teaching hospital. *BJU Int*, 2009. 104: 1109.
<http://www.ncbi.nlm.nih.gov/pubmed/19338562>
246. Vicente, J., *et al.* Value of electrical dispersion as a cause of urethral stenosis after endoscopic surgery. *Eur Urol*, 1992. 21: 280.
<http://www.ncbi.nlm.nih.gov/pubmed/1459149>
247. Komura, K., *et al.* Incidence of urethral stricture after bipolar transurethral resection of the prostate using TURis: results from a randomised trial. *BJU Int*, 2015. 115: 644.
<http://www.ncbi.nlm.nih.gov/pubmed/24909399>

248. Stucki, P., *et al.* Bipolar versus monopolar transurethral resection of the prostate: a prospective randomized trial focusing on bleeding complications. *J Urol*, 2015. 193: 1371.
<http://www.ncbi.nlm.nih.gov/pubmed/25464004>
249. Hammarsten, J., *et al.* Urethral strictures following transurethral resection of the prostate. The role of the catheter. *Br J Urol*, 1989. 63: 397.
<http://www.ncbi.nlm.nih.gov/pubmed/2713622>
250. Rassweiler, J., *et al.* Complications of transurethral resection of the prostate (TURP)--incidence, management, and prevention. *Eur Urol*, 2006. 50: 969.
<http://www.ncbi.nlm.nih.gov/pubmed/16469429>
251. Eltabey, M.A., *et al.* Holmium laser enucleation versus transurethral resection of the prostate. *Can J Urol*, 2010. 17: 5447.
<http://www.ncbi.nlm.nih.gov/pubmed/21172109>
252. Elliott, S.P., *et al.* Incidence of urethral stricture after primary treatment for prostate cancer: data From CaPSURE. *J Urol*, 2007. 178: 529.
<http://www.ncbi.nlm.nih.gov/pubmed/17570425>
253. Park, R., *et al.* Anastomotic strictures following radical prostatectomy: insights into incidence, effectiveness of intervention, effect on continence, and factors predisposing to occurrence. *Urology*, 2001. 57: 742.
<http://www.ncbi.nlm.nih.gov/pubmed/11306394>
254. Autorino, R., *et al.* Perioperative Outcomes of Robotic and Laparoscopic Simple Prostatectomy: A European-American Multi-institutional Analysis. *Eur Urol*, 2015. 68: 86.
<http://www.ncbi.nlm.nih.gov/pubmed/25484140>
255. Msezane, L.P., *et al.* Bladder neck contracture after robot-assisted laparoscopic radical prostatectomy: evaluation of incidence and risk factors and impact on urinary function. *J Endourol*, 2008. 22: 97.
<http://www.ncbi.nlm.nih.gov/pubmed/18326071>
256. Ficarra, V., *et al.* Retropubic, laparoscopic, and robot-assisted radical prostatectomy: a systematic review and cumulative analysis of comparative studies. *Eur Urol*, 2009. 55: 1037.
<http://www.ncbi.nlm.nih.gov/pubmed/19185977>
257. Chrouser, K.L., *et al.* Urinary fistulas following external radiation or permanent brachytherapy for the treatment of prostate cancer. *J Urol*, 2005. 173: 1953.
<http://www.ncbi.nlm.nih.gov/pubmed/15879789>
258. Marguet, C., *et al.* Rectourethral fistula after combination radiotherapy for prostate cancer. *Urology*, 2007. 69: 898.
<http://www.ncbi.nlm.nih.gov/pubmed/17482930>
259. Gomez-Iturriaga Pina, A., *et al.* Median 5 year follow-up of 125iodine brachytherapy as monotherapy in men aged <or=55 years with favorable prostate cancer. *Urology*, 2010. 75: 1412.
<http://www.ncbi.nlm.nih.gov/pubmed/20035986>
260. Fonteyne, V., *et al.* Urinary toxicity after high dose intensity modulated radiotherapy as primary therapy for prostate cancer. *Radiother Oncol*, 2009. 92: 42.
<http://www.ncbi.nlm.nih.gov/pubmed/19356817>
261. Shelley, M., *et al.* Cryotherapy for localised prostate cancer. *Cochrane Database Syst Rev*, 2007: CD005010.
<http://www.ncbi.nlm.nih.gov/pubmed/17636783>
262. Polat, O., *et al.* Iatrogenic injuries to ureter, bladder and urethra during abdominal and pelvic operations. *Int Urol Nephrol*, 1997. 29: 13.
<http://www.ncbi.nlm.nih.gov/pubmed/9203032>
263. Hautmann, R.E., *et al.* 25 years of experience with 1,000 neobladders: long-term complications. *J Urol*, 2011. 185: 2207.
<http://www.ncbi.nlm.nih.gov/pubmed/21497841>
264. Chapple, C., *et al.* Consensus statement on urethral trauma. *BJU Int*, 2004. 93: 1195.
<http://www.ncbi.nlm.nih.gov/pubmed/15180604>
265. Brandes, S. Initial management of anterior and posterior urethral injuries. *Urol Clin North Am*, 2006. 33: 87.
<http://www.ncbi.nlm.nih.gov/pubmed/16488283>
266. Park, S., *et al.* Straddle injuries to the bulbar urethra: management and outcomes in 78 patients. *J Urol*, 2004. 171: 722.
<http://www.ncbi.nlm.nih.gov/pubmed/14713796>

267. Elgammal, M.A. Straddle injuries to the bulbar urethra: management and outcome in 53 patients. *Int Braz J Urol*, 2009. 35: 450.
<http://www.ncbi.nlm.nih.gov/pubmed/19719861>
268. Kommu, S.S., *et al.* Patterns of urethral injury and immediate management. *Curr Opin Urol*, 2007. 17: 383.
<http://www.ncbi.nlm.nih.gov/pubmed/17921771>
269. Rosenstein, D.I., *et al.* Diagnosis and classification of urethral injuries. *Urol Clin North Am*, 2006. 33: 73.
<http://www.ncbi.nlm.nih.gov/pubmed/16488282>
270. Phonsombat, S., *et al.* Penetrating external genital trauma: a 30-year single institution experience. *J Urol*, 2008. 180: 192.
<http://www.ncbi.nlm.nih.gov/pubmed/18499189>
271. Simhan, J., *et al.* Gunshot wounds to the scrotum: a large single-institutional 20-year experience. *BJU Int*, 2012. 109: 1704.
<http://www.ncbi.nlm.nih.gov/pubmed/21992688>
272. Kunkle, D.A., *et al.* Evaluation and management of gunshot wounds of the penis: 20-year experience at an urban trauma center. *J Trauma*, 2008. 64: 1038.
<http://www.ncbi.nlm.nih.gov/pubmed/18404072>
273. Bjurlin, M.A., *et al.* Clinical characteristics and surgical outcomes of penetrating external genital injuries. *J Trauma Acute Care Surg*, 2013. 74: 839.
<http://www.ncbi.nlm.nih.gov/pubmed/23425745>
274. Amit, A., *et al.* Penile fracture and associated urethral injury: Experience at a tertiary care hospital. *Can Urol Assoc J*, 2013. 7: E168.
<http://www.ncbi.nlm.nih.gov/pubmed/23589751>
275. Lumen, N., *et al.* Etiology of urethral stricture disease in the 21st century. *J Urol*, 2009. 182: 983.
<http://www.ncbi.nlm.nih.gov/pubmed/19616805>
276. Palminteri, E., *et al.* Contemporary urethral stricture characteristics in the developed world. *Urology*, 2013. 81: 191.
<http://www.ncbi.nlm.nih.gov/pubmed/23153951>
277. Basta, A.M., *et al.* Predicting urethral injury from pelvic fracture patterns in male patients with blunt trauma. *J Urol*, 2007. 177: 571.
<http://www.ncbi.nlm.nih.gov/pubmed/17222635>
278. Barbagli, G., *et al.* The spectrum of pelvic fracture urethral injuries and posterior urethroplasty in an Italian high-volume centre, from 1980 to 2013. *Arab J Urol*, 2015. 13: 32.
<http://www.ncbi.nlm.nih.gov/pubmed/26019976>
279. Koraitim, M.M., *et al.* Risk factors and mechanism of urethral injury in pelvic fractures. *Br J Urol*, 1996. 77: 876.
<http://www.ncbi.nlm.nih.gov/pubmed/8705225>
280. Mundy, A.R., *et al.* Pelvic fracture-related injuries of the bladder neck and prostate: their nature, cause and management. *BJU Int*, 2010. 105: 1302.
<http://www.ncbi.nlm.nih.gov/pubmed/19874306>
281. Tausch, T.J., *et al.* Gunshot wound injuries of the prostate and posterior urethra: reconstructive armamentarium. *J Urol*, 2007. 178: 1346.
<http://www.ncbi.nlm.nih.gov/pubmed/17706720>
282. Koraitim, M.M. Predictors of erectile dysfunction post pelvic fracture urethral injuries: a multivariate analysis. *Urology*, 2013. 81: 1081.
<http://www.ncbi.nlm.nih.gov/pubmed/23465164>
283. Feng, C., *et al.* Risk factors for erectile dysfunction in patients with urethral strictures secondary to blunt trauma. *J Sex Med*, 2008. 5: 2656.
<http://www.ncbi.nlm.nih.gov/pubmed/18564154>
284. Metzke, M., *et al.* Male sexual dysfunction after pelvic fracture. *J Trauma*, 2007. 63: 394.
<http://www.ncbi.nlm.nih.gov/pubmed/17693842>
285. Bertrand, L.A., *et al.* Lower urinary tract pain and anterior urethral stricture disease: prevalence and effects of urethral reconstruction. *J Urol*, 2015. 193: 184.
<http://www.ncbi.nlm.nih.gov/pubmed/25046621>
286. Koraitim, M.M., *et al.* Role of magnetic resonance imaging in assessment of posterior urethral distraction defects. *Urology*, 2007. 70: 403.
<http://www.ncbi.nlm.nih.gov/pubmed/17905082>

287. Mundy, A.R., *et al.* Urethral trauma. Part II: Types of injury and their management. *BJU Int*, 2011. 108: 630.
<http://www.ncbi.nlm.nih.gov/pubmed/21854524>
288. Koraitim, M.M. Pelvic fracture urethral injuries: the unresolved controversy. *J Urol*, 1999. 161: 1433.
<http://www.ncbi.nlm.nih.gov/pubmed/10210368>
289. Ahl, R., *et al.* Digital rectal examination for initial assessment of the multi-injured patient: Can we depend on it? *Ann Med Surg (Lond)*, 2016. 9: 77.
<http://www.ncbi.nlm.nih.gov/pubmed/27489624>
290. Hadjizacharia, P., *et al.* Evaluation of immediate endoscopic realignment as a treatment modality for traumatic urethral injuries. *J Trauma*, 2008. 64: 1443.
<http://www.ncbi.nlm.nih.gov/pubmed/18545107>
291. Rieder, J., *et al.* Review of intentionally self-inflicted, accidental and iatrogenic foreign objects in the genitourinary tract. *Urol Int*, 2010. 84: 471.
<http://www.ncbi.nlm.nih.gov/pubmed/20224259>
292. Kielb, S.J., *et al.* Evaluation and management of traumatic posterior urethral disruption with flexible cystourethroscopy. *J Trauma*, 2001. 50: 36.
<http://www.ncbi.nlm.nih.gov/pubmed/11253761>
293. Mazaris, E.M., *et al.* Penile fractures: immediate surgical approach with a midline ventral incision. *BJU Int*, 2009. 104: 520.
<http://www.ncbi.nlm.nih.gov/pubmed/19239439>
294. Kamdar, C., *et al.* Penile fracture: preoperative evaluation and surgical technique for optimal patient outcome. *BJU Int*, 2008. 102: 1640.
<http://www.ncbi.nlm.nih.gov/pubmed/18710448>
295. Goonesinghe, S.K., *et al.* Flexible cystourethroscopy in the follow-up of posturethroplasty patients and characterisation of recurrences. *Eur Urol*, 2015. 68: 523.
<http://www.ncbi.nlm.nih.gov/pubmed/25913391>
296. Firmanto, R., *et al.* Early Realignment Versus Delayed Urethroplasty in Management of Pelvic Fracture Urethral Injury: A Meta-analysis. *Acta Med Indones*, 2016. 48: 99.
<http://www.ncbi.nlm.nih.gov/pubmed/27550878>
297. Mouraviev, V.B., *et al.* The treatment of posterior urethral disruption associated with pelvic fractures: comparative experience of early realignment versus delayed urethroplasty. *J Urol*, 2005. 173: 873.
<http://www.ncbi.nlm.nih.gov/pubmed/15711301>
298. Derouiche, A., *et al.* Management of penile fractures complicated by urethral rupture. *Int J Impot Res*, 2008. 20: 111.
<http://www.ncbi.nlm.nih.gov/pubmed/17673928>
299. Jack, G.S., *et al.* Current treatment options for penile fractures. *Rev Urol*, 2004. 6: 114.
<http://www.ncbi.nlm.nih.gov/pubmed/16985591>
300. Cavalcanti, A.G., *et al.* Management of urethral lesions in penile blunt trauma. *Int J Urol*, 2006. 13: 1218.
<http://www.ncbi.nlm.nih.gov/pubmed/16984556>
301. Koraitim, M.M. Pelvic fracture urethral injuries: evaluation of various methods of management. *J Urol*, 1996. 156: 1288.
<http://www.ncbi.nlm.nih.gov/pubmed/8808856>
302. Leddy, L.S., *et al.* Outcomes of endoscopic realignment of pelvic fracture associated urethral injuries at a level 1 trauma center. *J Urol*, 2012. 188: 174.
<http://www.ncbi.nlm.nih.gov/pubmed/22591965>
303. Moudouni, S.M., *et al.* Early endoscopic realignment of post-traumatic posterior urethral disruption. *Urology*, 2001. 57: 628.
<http://www.ncbi.nlm.nih.gov/pubmed/11306365>
304. Kulkarni, S.B., *et al.* Posterior urethral stricture after pelvic fracture urethral distraction defects in developing and developed countries, and choice of surgical technique. *J Urol*, 2010. 183: 1049.
<http://www.ncbi.nlm.nih.gov/pubmed/20092843>
305. Koraitim, M.M. Unsuccessful outcomes after posterior urethroplasty: definition, diagnosis, and treatment. *Urology*, 2012. 79: 1168.
<http://www.ncbi.nlm.nih.gov/pubmed/22449452>
306. Sofer, M., *et al.* Long-term results of early endoscopic realignment of complete posterior urethral disruption. *J Endourol*, 2010. 24: 1117.
<http://www.ncbi.nlm.nih.gov/pubmed/20590470>

307. Singh, B.P., *et al.* Impact of prior urethral manipulation on outcome of anastomotic urethroplasty for post-traumatic urethral stricture. *Urology*, 2010. 75: 179.
<http://www.ncbi.nlm.nih.gov/pubmed/19854488>
308. Lumen, N., *et al.* Perineal anastomotic urethroplasty for posttraumatic urethral stricture with or without previous urethral manipulations: a review of 61 cases with long-term followup. *J Urol*, 2009. 181: 1196.
<http://www.ncbi.nlm.nih.gov/pubmed/19152939>
309. Mundy, A.R. The role of delayed primary repair in the acute management of pelvic fracture injuries of the urethra. *Br J Urol*, 1991. 68: 273.
<http://www.ncbi.nlm.nih.gov/pubmed/1913069>
310. Aboutaieb, R., *et al.* [Surgical treatment of traumatic ruptures of the posterior urethra]. *Prog Urol*, 2000. 10: 58.
<http://www.ncbi.nlm.nih.gov/pubmed/10785920>
311. Sfaxi, M., *et al.* [Surgical treatment of post-traumatic complete urethral rupture: deferred urgent urethral suture or delayed repair?]. *Prog Urol*, 2006. 16: 464.
<http://www.ncbi.nlm.nih.gov/pubmed/17069041>
312. Elliott, D.S., *et al.* Long-term followup and evaluation of primary realignment of posterior urethral disruptions. *J Urol*, 1997. 157: 814.
<http://www.ncbi.nlm.nih.gov/pubmed/9072573>
313. Culty, T., *et al.* Anastomotic urethroplasty for posttraumatic urethral stricture: previous urethral manipulation has a negative impact on the final outcome. *J Urol*, 2007. 177: 1374.
<http://www.ncbi.nlm.nih.gov/pubmed/17382735>
314. Webster, G.D., *et al.* Repair of pelvic fracture posterior urethral defects using an elaborated perineal approach: experience with 74 cases. *J Urol*, 1991. 145: 744.
<http://www.ncbi.nlm.nih.gov/pubmed/2005693>
315. Kizer, W.S., *et al.* Simplified reconstruction of posterior urethral disruption defects: limited role of supracrural rerouting. *J Urol*, 2007. 177: 1378.
<http://www.ncbi.nlm.nih.gov/pubmed/17382736>
316. Koraitim, M.M. On the art of anastomotic posterior urethroplasty: a 27-year experience. *J Urol*, 2005. 173: 135.
<http://www.ncbi.nlm.nih.gov/pubmed/15592055>
317. Cooperberg, M.R., *et al.* Urethral reconstruction for traumatic posterior urethral disruption: outcomes of a 25-year experience. *J Urol*, 2007. 178: 2006.
<http://www.ncbi.nlm.nih.gov/pubmed/17869302>
318. Koraitim, M.M. Optimising the outcome after anastomotic posterior urethroplasty. *Arab J Urol*, 2015. 13: 27.
<http://www.ncbi.nlm.nih.gov/pubmed/26019975>
319. Koraitim, M.M., *et al.* Perineal repair of pelvic fracture urethral injury: in pursuit of a successful outcome. *BJU Int*, 2015. 116: 265.
<http://www.ncbi.nlm.nih.gov/pubmed/24552421>
320. Webster, G.D., *et al.* Salvage posterior urethroplasty after failed initial repair of pelvic fracture membranous urethral defects. *J Urol*, 1990. 144: 1370.
<http://www.ncbi.nlm.nih.gov/pubmed/2231930>
321. MacDiarmid, S., *et al.* The importance of accurate assessment and conservative management of the open bladder neck in patients with post-pelvic fracture membranous urethral distraction defects. *Br J Urol*, 1995. 75: 65.
<http://www.ncbi.nlm.nih.gov/pubmed/7850300>
322. Oosterlinck, W., *et al.* [Surgical treatment of urethral stenoses: technical aspects]. *Ann Urol (Paris)*, 2007. 41: 173.
<http://www.ncbi.nlm.nih.gov/pubmed/18260607>
323. Guo, H., *et al.* Experience with 32 Pelvic Fracture Urethral Defects Associated with Urethrorectal Fistulas: Transperineal Urethroplasty with Gracilis Muscle Interposition. *J Urol*, 2017. 198: 141.
<http://www.ncbi.nlm.nih.gov/pubmed/28161353>
324. Feng, C., *et al.* The relationship between erectile dysfunction and open urethroplasty: a systematic review and meta-analysis. *J Sex Med*, 2013. 10: 2060.
<http://www.ncbi.nlm.nih.gov/pubmed/23656595>
325. Levine, J., *et al.* Comparison of open and endoscopic treatment of posttraumatic posterior urethral strictures. *World J Surg*, 2001. 25: 1597.
<http://www.ncbi.nlm.nih.gov/pubmed/11775198>

326. Goel, M.C., *et al.* Endoscopic management of traumatic posterior urethral stricture: early results and followup. *J Urol*, 1997. 157: 95.
<http://www.ncbi.nlm.nih.gov/pubmed/8976224>
327. Singh, O., *et al.* Urogenital fistulas in women: 5-year experience at a single center. *Urol J*, 2010. 7: 35.
<http://www.ncbi.nlm.nih.gov/pubmed/20209454>
328. Gokalp, A., *et al.* How to manage acute urethral false passage due to intermittent catheterization in spinal cord injured patients who refused insertion of an indwelling catheter. *J Urol*, 2003. 169: 203.
<http://www.ncbi.nlm.nih.gov/pubmed/12478136>
329. Maheshwari, P.N., *et al.* Immediate endoscopic management of complete iatrogenic anterior urethral injuries: a case series with long-term results. *BMC Urol*, 2005. 5: 13.
<http://www.ncbi.nlm.nih.gov/pubmed/16281970>
330. Pansadoro, V., *et al.* Iatrogenic prostatic urethral strictures: classification and endoscopic treatment. *Urology*, 1999. 53: 784.
<http://www.ncbi.nlm.nih.gov/pubmed/10197857>
331. Monga, M., *et al.* Testicular Trauma. *Adolesc Med*, 1996. 7: 141.
<http://www.ncbi.nlm.nih.gov/pubmed/10359963>
332. Frauscher, F., *et al.* US findings in the scrotum of extreme mountain bikers. *Radiology*, 2001. 219: 427.
<http://www.ncbi.nlm.nih.gov/pubmed/11323467>
333. de Peretti, F., *et al.* [Fuel tanks of motorcycles. Role in severe trauma of the pelvis]. *Presse Med*, 1993. 22: 61.
<http://www.ncbi.nlm.nih.gov/pubmed/8493205>
334. Herrmann, B., *et al.* Genital injuries in prepubertal girls from inline skating accidents. *Pediatrics*, 2002. 110: e16.
<http://www.ncbi.nlm.nih.gov/pubmed/12165615>
335. Lawson, J.S., *et al.* Catastrophic injuries to the eyes and testicles in footballers. *Med J Aust*, 1995. 163: 242.
<http://www.ncbi.nlm.nih.gov/pubmed/7565208>
336. Selikowitz, S.M. Penetrating high-velocity genitourinary injuries. Part I. Statistics mechanisms, and renal wounds. *Urology*, 1977. 9: 371.
<http://www.ncbi.nlm.nih.gov/pubmed/855062>
337. Hudak, S.J., *et al.* Operative management of wartime genitourinary injuries at Balad Air Force Theater Hospital, 2005 to 2008. *J Urol*, 2009. 182: 180.
<http://www.ncbi.nlm.nih.gov/pubmed/19450817>
338. Cass, A.S., *et al.* Bilateral testicular injury from external trauma. *J Urol*, 1988. 140: 1435.
<http://www.ncbi.nlm.nih.gov/pubmed/3193512>
339. McAninch, J.W., *et al.* Major traumatic and septic genital injuries. *J Trauma*, 1984. 24: 291.
<http://www.ncbi.nlm.nih.gov/pubmed/6368854>
340. Michielsen, D., *et al.* Burns to the genitalia and the perineum. *J Urol*, 1998. 159: 418.
<http://www.ncbi.nlm.nih.gov/pubmed/9649253>
341. Nelius, T., *et al.* Genital piercings: diagnostic and therapeutic implications for urologists. *Urology*, 2011. 78: 998.
<http://www.ncbi.nlm.nih.gov/pubmed/22054364>
342. Goldman, H.B., *et al.* Traumatic injuries of the female external genitalia and their association with urological injuries. *J Urol*, 1998. 159: 956.
<http://www.ncbi.nlm.nih.gov/pubmed/9474191>
343. Husmann, D.A. Editorial Comment. *J Urol* 1998. 159: 959.
[http://www.jurology.com/article/S0022-5347\(01\)63782-0/abstract](http://www.jurology.com/article/S0022-5347(01)63782-0/abstract)
344. Donovan, J.F., *et al.* The therapy of genital trauma by dog bite. *J Urol*, 1989. 141: 1163.
<http://www.ncbi.nlm.nih.gov/pubmed/2651716>
345. Presutti, R.J. Prevention and treatment of dog bites. *Am Fam Physician*, 2001. 63: 1567.
<http://www.ncbi.nlm.nih.gov/pubmed/11327433>
346. Talan, D.A., *et al.* Bacteriologic analysis of infected dog and cat bites. Emergency Medicine Animal Bite Infection Study Group. *N Engl J Med*, 1999. 340: 85.
<http://www.ncbi.nlm.nih.gov/pubmed/9887159>
347. Presutti, R.J. Bite wounds. Early treatment and prophylaxis against infectious complications. *Postgrad Med*, 1997. 101: 243.
<http://www.ncbi.nlm.nih.gov/pubmed/9126216>

348. Lewis, K.T., *et al.* Management of cat and dog bites. *Am Fam Physician*, 1995. 52: 479.
<http://www.ncbi.nlm.nih.gov/pubmed/7625323>
349. Dreesen, D.W., *et al.* Current recommendations for the prophylaxis and treatment of rabies. *Drugs*, 1998. 56: 801.
<http://www.ncbi.nlm.nih.gov/pubmed/9829154>
350. Anderson, C.R. Animal bites. Guidelines to current management. *Postgrad Med*, 1992. 92: 134.
<http://www.ncbi.nlm.nih.gov/pubmed/1614928>
351. Gee S, *et al*, on behalf of the North West Policy Group. Guidance for the Management of Human Bite Injuries. 2010.
http://webarchive.nationalarchives.gov.uk/20140714113432/http://www.hpa.org.uk/webc/HPAwebFile/HPAweb_C/1194947350692
352. Gaspar, S.S., *et al.* Sexual Urological Emergencies. *Sexual Medicine Reviews*, 2015. 3: 93.
<http://www.ncbi.nlm.nih.gov/pubmed/27784550>
353. McGregor, M.J., *et al.* Sexual assault forensic medical examination: is evidence related to successful prosecution? *Ann Emerg Med*, 2002. 39: 639.
<http://www.ncbi.nlm.nih.gov/pubmed/12023707>
354. Okur, H., *et al.* Genitourinary tract injuries in girls. *Br J Urol*, 1996. 78: 446.
<http://www.ncbi.nlm.nih.gov/pubmed/8881959>
355. U.S. Department of Justice, Office on Violence Against Women. A National Protocol for Sexual Assault Medical Forensic Examinations: Adults/Adolescents. 2013:2nd edn.
<https://www.ncjrs.gov/pdffiles1/ovw/241903.pdf>
356. Amer, T., *et al.* Penile Fracture: A Meta-Analysis. *Urol Int*, 2016. 96: 315.
<http://www.ncbi.nlm.nih.gov/pubmed/26953932>
357. Haas, C.A., *et al.* Penile fracture and testicular rupture. *World J Urol*, 1999. 17: 101.
<http://www.ncbi.nlm.nih.gov/pubmed/10367369>
358. Nicolaisen, G.S., *et al.* Rupture of the corpus cavernosum: surgical management. *J Urol*, 1983. 130: 917.
<http://www.ncbi.nlm.nih.gov/pubmed/6632099>
359. Tsang, T., *et al.* Penile fracture with urethral injury. *J Urol*, 1992. 147: 466.
<http://www.ncbi.nlm.nih.gov/pubmed/1732623>
360. De Luca, F., *et al.* Functional outcomes following immediate repair of penile fracture: a tertiary referral centre experience with 76 consecutive patients. *Scand J Urol*, 2017. 51: 170.
<http://www.ncbi.nlm.nih.gov/pubmed/28125311>
361. Mydlo, J.H., *et al.* Urethrography and cavernosography imaging in a small series of penile fractures: a comparison with surgical findings. *Urology*, 1998. 51: 616.
<http://www.ncbi.nlm.nih.gov/pubmed/9586616>
362. Lee, S.H., *et al.* Trauma to male genital organs: a 10-year review of 156 patients, including 118 treated by surgery. *BJU Int*, 2008. 101: 211.
<http://www.ncbi.nlm.nih.gov/pubmed/17922859>
363. Karadeniz, T., *et al.* Penile fracture: differential diagnosis, management and outcome. *Br J Urol*, 1996. 77: 279.
<http://www.ncbi.nlm.nih.gov/pubmed/8800899>
364. Fedel, M., *et al.* The value of magnetic resonance imaging in the diagnosis of suspected penile fracture with atypical clinical findings. *J Urol*, 1996. 155: 1924.
<http://www.ncbi.nlm.nih.gov/pubmed/8618289>
365. Pretorius, E.S., *et al.* MR imaging of the penis. *Radiographics*, 2001. 21 Spec No: S283.
<http://www.ncbi.nlm.nih.gov/pubmed/11598264>
366. Uder, M., *et al.* MRI of penile fracture: diagnosis and therapeutic follow-up. *Eur Radiol*, 2002. 12: 113.
<http://www.ncbi.nlm.nih.gov/pubmed/11868085>
367. Summerton, D.J., *et al.* Reconstructive surgery in penile trauma and cancer. *Nat Clin Pract Urol*, 2005. 2: 391.
<http://www.ncbi.nlm.nih.gov/pubmed/16474736>
368. Penbegul, N., *et al.* No evidence of depression, anxiety, and sexual dysfunction following penile fracture. *Int J Impot Res*, 2012. 24: 26.
<http://www.ncbi.nlm.nih.gov/pubmed/21918532>
369. Orvis, B.R., *et al.* Penile rupture. *Urol Clin North Am*, 1989. 16: 369.
<http://www.ncbi.nlm.nih.gov/pubmed/2652861>

370. Virasoro, R., *et al.* Penile Amputation: Cosmetic and Functional Results. *Sexual Medicine Reviews*, 2015. 3: 214.
<http://www.ncbi.nlm.nih.gov/pubmed/27784611>
371. Babaei, A.R., *et al.* Penile replantation, science or myth? A systematic review. *Urol J*, 2007. 4: 62.
<http://www.ncbi.nlm.nih.gov/pubmed/17701923>
372. Lee, J.Y., *et al.* Traumatic dislocation of testes and bladder rupture. *Urology*, 1992. 40: 506.
<http://www.ncbi.nlm.nih.gov/pubmed/1466102>
373. Nagarajan, V.P., *et al.* Traumatic dislocation of testis. *Urology*, 1983. 22: 521.
<http://www.ncbi.nlm.nih.gov/pubmed/6649208>
374. Pollen, J.J., *et al.* Traumatic dislocation of the testes. *J Trauma*, 1982. 22: 247.
<http://www.ncbi.nlm.nih.gov/pubmed/7069812>
375. Shefi, S., *et al.* Traumatic testicular dislocation: a case report and review of published reports. *Urology*, 1999. 54: 744.
<http://www.ncbi.nlm.nih.gov/pubmed/10754145>
376. Tiguert, R., *et al.* Management of shotgun injuries to the pelvis and lower genitourinary system. *Urology*, 2000. 55: 193.
<http://www.ncbi.nlm.nih.gov/pubmed/10688077>
377. Altarac, S. Management of 53 cases of testicular trauma. *Eur Urol*, 1994. 25: 119.
<http://www.ncbi.nlm.nih.gov/pubmed/8137851>
378. Cass, A.S., *et al.* Value of early operation in blunt testicular contusion with hematocele. *J Urol*, 1988. 139: 746.
<http://www.ncbi.nlm.nih.gov/pubmed/3352037>
379. Cass, A.S., *et al.* Testicular injuries. *Urology*, 1991. 37: 528.
<http://www.ncbi.nlm.nih.gov/pubmed/2038785>
380. Wang, Z., *et al.* Diagnosis and management of testicular rupture after blunt scrotal trauma: a literature review. *Int Urol Nephrol*, 2016. 48: 1967.
<http://www.ncbi.nlm.nih.gov/pubmed/27567912>
381. Wasko, R., *et al.* Traumatic rupture of the testicle. *J Urol*, 1966. 95: 721.
<http://www.ncbi.nlm.nih.gov/pubmed/5935538>
382. Andipa, E., *et al.* Magnetic resonance imaging and ultrasound evaluation of penile and testicular masses. *World J Urol*, 2004. 22: 382.
<http://www.ncbi.nlm.nih.gov/pubmed/15300391>
383. Corrales, J.G., *et al.* Accuracy of ultrasound diagnosis after blunt testicular trauma. *J Urol*, 1993. 150: 1834.
<http://www.ncbi.nlm.nih.gov/pubmed/8080482>
384. Fournier, G.R., Jr., *et al.* Scrotal ultrasonography and the management of testicular trauma. *Urol Clin North Am*, 1989. 16: 377.
<http://www.ncbi.nlm.nih.gov/pubmed/2652862>
385. Kratzik, C., *et al.* Has ultrasound influenced the therapy concept of blunt scrotal trauma? *J Urol*, 1989. 142: 1243.
<http://www.ncbi.nlm.nih.gov/pubmed/2681835>
386. Martinez-Pineiro, L., Jr., *et al.* Value of testicular ultrasound in the evaluation of blunt scrotal trauma without haematocele. *Br J Urol*, 1992. 69: 286.
<http://www.ncbi.nlm.nih.gov/pubmed/1568102>
387. Micallef, M., *et al.* Ultrasound features of blunt testicular injury. *Injury*, 2001. 32: 23.
<http://www.ncbi.nlm.nih.gov/pubmed/11164397>
388. Mulhall, J.P., *et al.* Emergency management of blunt testicular trauma. *Acad Emerg Med*, 1995. 2: 639.
<http://www.ncbi.nlm.nih.gov/pubmed/8521212>
389. Patil, M.G., *et al.* The value of ultrasound in the evaluation of patients with blunt scrotal trauma. *Injury*, 1994. 25: 177.
<http://www.ncbi.nlm.nih.gov/pubmed/8168890>
390. Churukanti, G.R., *et al.* Role of Ultrasonography for Testicular Injuries in Penetrating Scrotal Trauma. *Urology*, 2016. 95: 208.
<http://www.ncbi.nlm.nih.gov/pubmed/27132505>
391. Muglia, V., *et al.* Magnetic resonance imaging of scrotal diseases: when it makes the difference. *Urology*, 2002. 59: 419.
<http://www.ncbi.nlm.nih.gov/pubmed/11880084>
392. Altarac, S. A case of testicle replantation. *J Urol*, 1993. 150: 1507.
<http://www.ncbi.nlm.nih.gov/pubmed/8411440>

393. Tchounzou, R., *et al.* Retrospective Analysis of Clinical Features, Treatment and Outcome of Coital Injuries of the Female Genital Tract Consecutive to Consensual Sexual Intercourse in the Limbe Regional Hospital. *Sex Med*, 2015. 3: 256.
<http://www.ncbi.nlm.nih.gov/pubmed/26797059>
394. Sotto, L.S., *et al.* Perigenital hematomas; analysis of forty-seven consecutive cases. *Obstet Gynecol*, 1958. 12: 259.
<http://www.ncbi.nlm.nih.gov/pubmed/13578292>
395. McWilliams, G.D., *et al.* Gynecologic emergencies. *Surg Clin North Am*, 2008. 88: 265.
<http://www.ncbi.nlm.nih.gov/pubmed/18381113>
396. Virgili, A., *et al.* Serious hematoma of the vulva from a bicycle accident. A case report. *J Reprod Med*, 2000. 45: 662.
<http://www.ncbi.nlm.nih.gov/pubmed/10986686>
397. Monstrey, S.J., *et al.* Urological trauma and severe associated injuries. *Br J Urol*, 1987. 60: 393.
<http://www.ncbi.nlm.nih.gov/pubmed/3427315>
398. MacKenzie, E.J., *et al.* A national evaluation of the effect of trauma-center care on mortality. *N Engl J Med*, 2006. 354: 366.
<http://www.ncbi.nlm.nih.gov/pubmed/16436768>
399. Caterson, E.J., *et al.* Boston bombings: a surgical view of lessons learned from combat casualty care and the applicability to Boston's terrorist attack. *J Craniofac Surg*, 2013. 24: 1061.
<http://www.ncbi.nlm.nih.gov/pubmed/23851738>
400. Dutton, R.P., *et al.* Daily multidisciplinary rounds shorten length of stay for trauma patients. *J Trauma*, 2003. 55: 913.
<http://www.ncbi.nlm.nih.gov/pubmed/14608165>
401. Makanjuola, J.K., *et al.* Centralisation of major trauma: an opportunity for acute urology services in the UK. *BJU Int*, 2012. 109: 173.
<http://www.ncbi.nlm.nih.gov/pubmed/22212283>
402. Feliciano DV, Moore EE., Mattox KL. , Trauma damage control, in Trauma, Feliciano DV, Mattox KL, Moore EE, Eds. 2000, McGraw-Hill: New York.
403. Hirshberg, A., *et al.* 'Damage control' in trauma surgery. *Br J Surg*, 1993. 80: 1501.
<http://www.ncbi.nlm.nih.gov/pubmed/8298911>
404. Rignault, D.P. Recent progress in surgery for the victims of disaster, terrorism, and war--Introduction. *World J Surg*, 1992. 16: 885.
<http://www.ncbi.nlm.nih.gov/pubmed/1462624>
405. Rotondo, M.F., *et al.* 'Damage control': an approach for improved survival in exsanguinating penetrating abdominal injury. *J Trauma*, 1993. 35: 375.
<http://www.ncbi.nlm.nih.gov/pubmed/8371295>
406. Mercer, S.J., *et al.* Lessons from the battlefield: human factors in defence anaesthesia. *Br J Anaesth*, 2010. 105: 9.
<http://www.ncbi.nlm.nih.gov/pubmed/20551025>
407. Holcomb, J.B., *et al.* Military, civilian, and rural application of the damage control philosophy. *Mil Med*, 2001. 166: 490.
<http://www.ncbi.nlm.nih.gov/pubmed/11413725>
408. Brandes, S.B., *et al.* Renal trauma: a practical guide to evaluation and management. *ScientificWorldJournal*, 2004. 4 Suppl 1: 31.
<http://www.ncbi.nlm.nih.gov/pubmed/15349524>
409. Hirshberg A, M.K., Top Knife: the Art and Craft of Trauma Surgery. 2005, TFM Publishing Ltd. : Shrewsbury, UK.
<http://www.tfmpublishing.com/top-knife-the-art-craft-of-trauma-surgery>
410. Ptohis, N.D., *et al.* Contemporary Role of Embolization of Solid Organ and Pelvic Injuries in Polytrauma Patients. *Front Surg*, 2017. 4: 43.
<http://www.ncbi.nlm.nih.gov/pubmed/28824919>
411. Best, C.D., *et al.* Traumatic ureteral injuries: a single institution experience validating the American Association for the Surgery of Trauma--Organ Injury Scale grading scale. *J Urol*, 2005. 173: 1202.
<http://www.ncbi.nlm.nih.gov/pubmed/15758748>
412. Hirshberg, A., *et al.* Planned reoperation for trauma: a two year experience with 124 consecutive patients. *J Trauma*, 1994. 37: 365.
<http://www.ncbi.nlm.nih.gov/pubmed/8083894>
413. Gomez, R.G., *et al.* Consensus statement on bladder injuries. *BJU Int*, 2004. 94: 27.
<http://www.ncbi.nlm.nih.gov/pubmed/15217426>

414. van der Horst, C., *et al.* Male genital injury: diagnostics and treatment. *BJU Int*, 2004. 93: 927.
<http://www.ncbi.nlm.nih.gov/pubmed/15142139>
415. Gross, M. Rupture of the testicle: the importance of early surgical treatment. *J Urol*, 1969. 101: 196.
<http://www.ncbi.nlm.nih.gov/pubmed/5765482>
416. Slater, M.S., *et al.* Terrorism in America. An evolving threat. *Arch Surg*, 1997. 132: 1059.
<http://www.ncbi.nlm.nih.gov/pubmed/9336502>
417. Caro, D. Major disasters. *Lancet*, 1974. 2: 1309.
<http://www.ncbi.nlm.nih.gov/pubmed/4139541>
418. Weight JA, K.B., Ali J, *et al.* American College of Surgeons Committee on Trauma, Advanced Trauma Life Support Student Course Manual. 6th ed. 1997, Chicago.
419. National Audit Office, Treating Injury and Illness arising on Military Operations. February 2010.
<https://www.nao.org.uk/report/ministry-of-defence-treating-injury-and-illness-arising-on-military-operations/>
420. Frykberg, E.R. Medical management of disasters and mass casualties from terrorist bombings: how can we cope? *J Trauma*, 2002. 53: 201.
<http://www.ncbi.nlm.nih.gov/pubmed/12169923>
421. Jacobs, L.M., Jr., *et al.* An emergency medical system approach to disaster planning. *J Trauma*, 1979. 19: 157.
<http://www.ncbi.nlm.nih.gov/pubmed/458880>

7. CONFLICT OF INTEREST

All members of the Urological Trauma Guidelines working group have provided disclosure statements of all relationships that they have that might be perceived as a potential source of a conflict of interest. This information is publically accessible through the European Association of Urology website: <http://uroweb.org/guideline/urological-trauma/?type=panel>. This guidelines document was developed with the financial support of the European Association of Urology. No external sources of funding and support have been involved. The EAU is a non-profit organisation and funding is limited to administrative assistance and travel and meeting expenses. No honoraria or other reimbursements have been provided.

8. CITATION INFORMATION

The format in which to cite the EAU Guidelines will vary depending on the style guide of the journal in which the citation appears. Accordingly, the number of authors or whether, for instance, to include the publisher, location, or an ISBN number may vary.

The compilation of the complete Guidelines should be referenced as:

EAU Guidelines. Edn. presented at the EAU Annual Congress Copenhagen 2018. ISBN 978-94-92671-01-1.

If a publisher and/or location is required, include:

EAU Guidelines Office, Arnhem, The Netherlands. <http://uroweb.org/guidelines/compilations-of-all-guidelines/>

References to individual guidelines should be structured in the following way:

Contributors' names. Title of resource. Publication type. ISBN. Publisher and publisher location, year.