



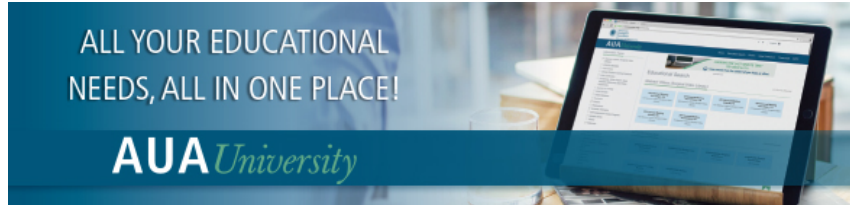Advancing Urology™

Journal of Urology
Guidelines
Annual Meeting 2017
Are you a Patient?

ABOUT US EDUCATION RESEARCH ADVOCACY INTERNATIONAL PRACTICE RESOURCES

[EDUCATION](#) > [Educational Programs](#) > [Education for Medical Students](#) > [Medical Student Curriculum](#) > [Acute Scrotum](#)

Medical Student Curriculum



ADVERTISEMENT

ADVERTISEMENT

ACUTE SCROTUM

This document was amended in July 2016 to reflect literature that was released since the original publication of this content in May 2012. This document will continue to be periodically updated to reflect the growing body of literature related to this topic.

KEY WORDS: Testis, epididymis, torsion, epididymitis, ischemia, tumor, infection, hernia

Learning Objectives

At the end of medical school, the student should be able to:

1. Describe 6 conditions that may produce acute scrotal pain or swelling.
2. Distinguish, through the history, physical examination and laboratory testing, testicular torsion, torsion of testicular appendices, epididymitis, testicular tumor, scrotal trauma and hernia.
3. Appropriately order imaging studies to make the diagnosis of the acute scrotum.
4. Determine which acute scrotal conditions require emergent surgery and which may be handled less emergently or electively.

Introduction

The "acute scrotum" may be viewed as the urologist's equivalent to the general surgeon's "acute abdomen." Both conditions are guided by similar management principles:

- The patient history and physical examination are key to the diagnosis and often guide decision making regarding whether or not surgical intervention is appropriate.
- Imaging studies should complement, but not replace, sound clinical judgment.
- When making a decision for conservative, non-surgical care, the provider must balance the potential morbidity of surgical exploration against the potential cost of missing a surgical diagnosis.
- A small but real, negative exploration rate is acceptable to minimize the risk of missing a critical surgical diagnosis.

Differential Diagnosis of the Acute Scrotum

A list of potential medical conditions that can present as acute pain or swelling of the scrotum are found in **Table 1**.

Table 1. Causes of Acute Scrotal Pain and Swelling

Ischemia:

Torsion of the testis (synonymous with torsion of the spermatic cord) Intravaginal; extravaginal (prenatal or neonatal)
Appendiceal torsion, testis or epididymis
Testicular infarction due to other vascular insult (cord injury, thrombosis)

Trauma:

Testicular rupture
Intratesticular hematoma, testicular contusion
Hematocele

Infectious conditions:

Acute epididymitis
Acute epididym orchitis

Acute or chitis
Abscess (intratesticular, intravaginal, scrotal cutaneous cysts) Gangrenous infections
(Fournier's gangrene)

Inflammatory conditions:

Henoch-Schonlein purpura (HSP) vasculitis of scrotal wall
Fat necrosis, scrotal wall

Hernia:

Incarcerated, strangulated inguinal hernia, with or without associated testicular ischemia

Acute on chronic events:

Spermatocele, rupture or hemorrhage
Hydrocele, rupture, hemorrhage or infection
Testicular tumor with rupture, hemorrhage, infarction or infection
Varicocele

While the differential diagnosis is broad, an accurate history and physical examination can frequently precisely define the condition. Often, carefully chosen imaging studies can complement clinical judgment and expedite therapeutic decisions. A discussion of the most important and common conditions that cause acute scrotal pain or swelling follows.

Torsion

Testicular Torsion

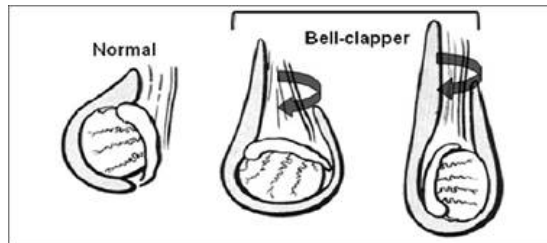


Figure 1. Bell clapper deformity. Normal testis lie is on the left and the classic "bell clapper" lie is in the middle. The right side shows a bell clapper variation.

The testicle is typically covered by the tunica vaginalis, creating a potential space around the testis. Normally, the tunica vaginalis attaches to the posterior surface of the testicle and allows for very little mobility of the testicle within the scrotum. Some patients have an inappropriately high attachment of the tunica vaginalis, such that the testicle can rotate freely on the spermatic cord within the tunica vaginalis (intravaginal testicular torsion) (Figure 1). This congenital anomaly, called the "bell clapper deformity," consists of a transverse as opposed to longitudinal lie of the affected testis; it can be unilateral or bilateral and is a risk factor for a torsion event. This congenital abnormality is present in approximately 12% of human males. During testis torsion, the testicle twists spontaneously on the spermatic cord, causing venous occlusion and engorgement, with subsequent arterial ischemia and infarction. Experimental evidence indicates that 720° twist is required to compromise flow through the testicular artery and result in ischemia. In neonates, the testicle frequently has not yet descended into the scrotum, after which it becomes attached within the tunica vaginalis. This increased mobility of the testicle predisposes it to torsion (extravaginal testicular torsion).

Testis torsion is the most common cause of testis loss in the US. The incidence in males <25 years old is approximately 1:4000. Torsion more often involves the left testicle. Among neonatal testicular torsion cases, 70% occur prenatally and 30% occur postnatally. The testis salvage rate approaches 100% in patients who undergo detorsion within 6 hours of the start of pain. However, there is only a 20% viability rate if detorsion occurs >12 hours; and virtually no viability if detorsion is delayed >24 hours (**Figure 2**).

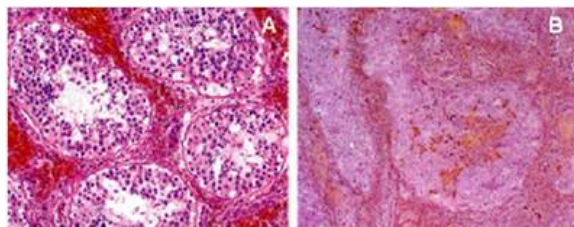


Figure 2. Testis histology during early A) hemorrhagic phase and chronic late (B) phases of testis torsion. Note the decreased seminiferous tubule diameter and loss of germ cells in late relative to early phases.

Testicular torsion presents with the rapid onset of severe testicular pain and swelling. The onset of pain may be preceded by trauma, physical activity, or by no activity (e.g. during sleep). It most often occurs in children or adolescents, but this diagnosis should be considered in evaluating men with scrotal pain of any age, as it may occasionally occur in men 40-50 years old. In this age group, the diagnosis is often delayed or missed due to a low suspicion because of age. Torsion should be in the differential for **any** sudden acute scrotal pain or swelling.

The classic physical examination findings with testis torsion are an exquisitely tender testicle with a high, horizontal lie. Normally the testicle has a vertical lie within the tunica vaginalis of the scrotum – that is, the longitudinal axis of the testis is oriented vertically. With torsion and twisting of the spermatic cord, the testis may assume an altered lie based on the degree of twisting. After venous outflow is occluded, there is swelling and occlusion of arterial flow. Early on, one may be able to palpate the torsed cord and the testis below it; later in the course,

however, progressive edema and inflammation ensues, such that after 12-24 hours, the entire hemiscrotum appears as a confluent mass without identifiable landmarks. At this stage, the physical examination may be indistinguishable from that seen with epididymoorchitis. Importantly, with torsion, signs of infection are usually absent: patients are usually afebrile, free of irritative voiding symptoms such as dysuria, and harbor a normal urinalysis and normal white blood cell count. (In later torsion, however, an elevated WBC may be seen in response to the inflammation).

With a high degree of suspicion, one may reasonably recommend surgical exploration without delay. If scrotal ultrasonography is readily available, and especially if the diagnosis is questionable, this test is the single most useful adjunct to the history and physical examination in the diagnosis of torsion. The ultrasonographer should use Doppler flow to assess arterial flow within the affected testis; if arterial flow is absent, torsion is highly likely. It is helpful to compare the flow patterns between both testes to help make this diagnosis. Ultrasonography may also exclude significant testicular trauma, show a hernia extending into the scrotum, and can distinguish epididymitis from torsion by demonstrating increased flow to the epididymis and adnexal structures along with preserved testicular perfusion. Beware of the ultrasonographer who suggests that a "complex mass" exists above the testis that might represent an inflamed epididymis; the torted cord with edema and inflammation is difficult to distinguish from an inflamed epididymis in torsion. Remember, *testicular perfusion* is the key to the ultrasound diagnosis of torsion. Tests such as nuclear testicular scans, CT or MRI, have essentially no role in the contemporary management of the acute scrotum.

When torsion is diagnosed, urgent surgical exploration and detorsion is mandated, as testicular torsion is a true vascular emergency. Testicular preservation is excellent when corrected within 4-6 hours of onset. Beyond 12 hours, the risk of subsequent testis atrophy is significant with detorsion. Testis salvage is often still appropriate if the testicular appearance at exploration improves with observation following detorsion. The alternative to detorsion is scrotal orchiectomy for pain relief in affected patients. After sharply entering the scrotum, the tunica vaginalis opened, the testis detorsed and wrapped in a warm, moist gauze. The contralateral side then undergoes orchidopexy to prevent torsion on that side. The affected testis is reinspected for signs of improved perfusion ("pinkening up") (**Figure 3**). If the testis appears viable, or the timeframe suggests that salvage is reasonable then orchiopey is performed by anchoring the tunica albuginea of the testis to the overlying parietal tunica vaginalis and scrotal dartos muscle.

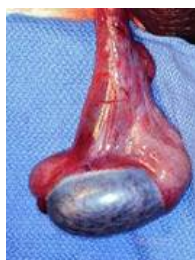

Figure 3. Exploration of torsed testis. Note dark, cyanotic color of testis following 30 minutes of detorsion suggesting nonviability.

In general, scrotal exploration is a procedure of low morbidity. A negative exploration seldom results in long term complications. When weighing conservative treatment with the loss of a potentially salvageable testis, it is best to err on the side of exploration. In cases of "late torsion" or "established torsion" exploration generally reveals a hemorrhagic, frankly necrotic testis for which orchiectomy should be performed.

"Intermittent" testicular torsion is a well recognized entity in which a classic torsion history is obtained, but physical examination and ultrasound findings are normal. In such cases, it is reasonable to offer an elective bilateral scrotal orchiopey for the possibility of intermittent symptoms becoming full fledged torsion.

Torsion of Testicular or Epididymal Appendages

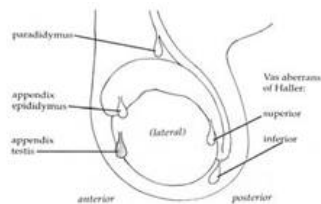


Figure 4. Illustration of the common appendices of the testis and epididymis. The appendix testis is most commonly affected by torsion.

Small polypoid appendages are often found attached to the testis or epididymis and are either Mullerian or Wolffian duct remnants (**Figure 4**). Similar to testis torsion, torsion of the appendix testis or appendix epididymis can also present with the acute onset of scrotal pain and mass. In most cases, however, the testis is palpable and has a normal lie. If encountered early, the edematous, torted appendage can often be palpated at the upper pole of the testis. If the torted appendage is ecchymotic, it can usually be seen through the skin and represents the "blue-dot sign." Doppler ultrasound will demonstrate a normally perfused testis, often with hypervascularity in the area of the appendage. This process is often self-limited, with the infarcted appendage undergoing atrophy with time. If exploration is pursued, the appendage is simply excised and no orchidopexy is needed. Later in its course, it can be more difficult to

distinguish this entity from testicular torsion or epididymitis, as global enlargement and edema of the scrotal compartment may occur. Ultrasound is valuable here to identify normal blood flow to the testis.

Trauma

Penetrating and Blunt Testicular Injury

Testicular rupture results when there is laceration of the tunica albuginea of the testis, such that testicular parenchyma may extrude. It may occur from either blunt or penetrating trauma. As a general principle, penetrating injuries to the scrotum should be surgically explored. The risk of testicular injury is quite high with these injuries. Even penetrating injuries with a tangential trajectory have a high likelihood of injuring the testis. In cases of blunt trauma, however, the incidence of testicular rupture varies widely, and depends on the forces exerted, the mechanism of injury, and testis mobility. Following blunt injury, the physical examination findings may include swelling, tenderness or ecchymosis. If one can clearly palpate the testis and it is entirely normal to palpation, rupture is unlikely. If there is significant scrotal wall thickening from edema or hematoma, testicular palpation may be difficult or impossible, and scrotal ultrasonography can determine the degree of testis injury. In addition to demonstrating a break in the continuity of the tunica albuginea or evidence of extruded parenchyma, ultrasound evidence of a marked loss of internal homogeneity of the testis is highly predictive of testicular rupture and warrants surgical exploration. Blunt injury may result in testicular rupture, intratesticular hematoma, testicular contusion (bruising) or hematocele (blood collection within the tunica vaginalis space). Among these, only testicular rupture requires surgical repair. Large or painful hematoceles may benefit from drainage. For intratesticular hematoma (intact tunica albuginea, localized hematoma within an otherwise intact testis) or local tenderness (contusion), observation, rest, cold packs and analgesics are appropriate therapy.

Surgical exploration for trauma is performed through incisions that anticipate the structures at risk. For penetrating trauma, a vertical incision may be easily extended into the groin to expose the spermatic cord. For blunt trauma, a transverse incision over the injured scrotal compartment is effective. After inspecting and draining the tunica vaginalis space, any extruded testicular parenchyma is inspected, irrigated and resected or retained and tunical lacerations repaired. The testicular compartment may be drained, generally with a small Penrose drain. With trauma, most testicular injuries are amenable to repair. Orchiectomy is indicated when there is major injury to the spermatic cord with organ devitalization, and destruction of parenchyma is so extensive that no significant tissue can be salvaged.

Infections

Epididymitis and Epididymo-orchitis

Although they may be difficult to distinguish on physical examination from scrotal trauma or testis torsion, it is important to accurately diagnose epididymitis and orchitis, as their management is entirely nonsurgical. Epididymitis is usually caused by infections. In men < 35 years old with a history of sexually transmitted infection (STI) exposure, recent sexual activity, epididymitis is often caused by Chlamydia or gonococcal infection, and is amenable to standard antibiotic treatment. In older men and those with problems such as significant benign prostatic hypertrophy (BPH), a history of UTI, or urethral stricture disease, enteric, gram negative bacteria related to ascending urinary infection are much more likely causes. In either case, initial broad spectrum antibiotics are used with therapy further directed based on culture results. There are also noninfectious or inflammatory forms of epididymitis. These are due to the adverse effects of medications, urinary reflux within the ejaculatory ducts, and sperm and fluid extravasation after vasectomy. When epididymitis extends into the testis and causes testicular tenderness and enlargement, it is termed epididymo-orchitis.

There are several features in the patient history that may indicate epididymitis, such as a history of previous STI, recent sexual activity, irritative voiding symptoms, BPH/incomplete emptying of the bladder, or UTI. The very sudden onset of pain and swelling is more typical of torsion, while a more gradual, progressive onset pain (often greater than 24 hours) suggests epididymitis. On physical examination, epididymitis presents with tenderness posterior and lateral to the testis (the usual location of the epididymis). Scrotal ultrasound may show an enlarged, hypervascular epididymis with normal or increased blood flow to the testis, which will distinguish this condition from torsion or trauma. Abscess formation within the epididymis or in the peri-epididymal tissues, can also be detected by ultrasound. The diagnostic challenge occurs when trying to distinguish advanced epididymo-orchitis from late torsion. In both entities, there is typically a confluent mass in the scrotum with edema and fixation of the overlying scrotal wall that obliterate normal anatomic landmarks. Furthermore, advanced epididymo-orchitis can result in testicular ischemia and infarction due to compression of the testicular vasculature from epididymal inflammation. On ultrasound, this may present in a very similar manner to testis torsion. In either case, the lack of testis blood flow on Doppler ultrasound requires surgical exploration which allows these conditions to be differentiated.

When diagnosed, epididymitis and orchitis are managed conservatively with antibiotics, anti-inflammatories, analgesics, rest and scrotal elevation. If abscess formation occurs, surgical drainage and/or orchiectomy may be necessary.

Scrotal Wall Infections

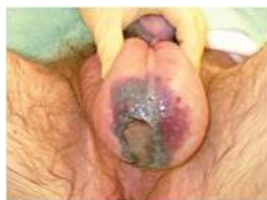

Figure 5. Fournier's gangrene of the scrotum.

Infectious conditions within the scrotal wall are also classified under the acute scrotum and include cellulitis and fasciitis (gangrene). Scrotal wall cellulitides and abscess formation are distinguishable testicular conditions on physical examination, as the testis is usually palpably normal and nontender, if it can be palpated without compressing the inflamed scrotal wall. Scrotal wall infections may result from infected sebaceous cysts, folliculitis, or other dermatologic conditions. Incision and drainage with gauze packing and broad-spectrum antibiotics are prescribed for these superficial conditions. Fasciitis of scrotum and groin, termed Fournier's gangrene, involves a rapidly progressive, life threatening infection of the genital soft tissues. It is associated with predisposing issues including urethral perforation and periurethral abscess and is most often seen in the immunocompromised or diabetic patient. On physical examination, there can be diffuse enlargement, thickening and erythema of the scrotal wall, groin and perineum. There may be necrotic black or ecchymotic patches of genital skin present (**Figure 5**).

Note necrotic, black patch of scrotal skin with large ulceration. (From: Aho T et al. (2006) Fournier's gangrene Nat Clin Pract Urol 3: 54–57)

The most diagnostic is the finding of crepitus, a spongy, cracking feeling within the skin that indicates gas-producing microorganisms underneath that can be felt in the scrotum or perineum. When left untreated, genital gangrene will progress over hours and result in overwhelming bacterial sepsis with an associated high mortality rate. Therefore, broad spectrum antibiotics that cover aerobic and anaerobic organisms, and urgent and repeated surgical drainage and debridement are required to control the infection. At the time of surgical treatment, cystoscopy and proctoscopy may be performed to exclude urethral and rectal abnormalities.

Scrotal Wall Inflammation

Henoch-Schonlein purpura (HSP) is a vasculitis of scrotal wall that causes thickening and erythema in the absence of infection. Idiopathic scrotal edema and filarial infections (rare in the US) can also cause chronic, relatively painless, scrotal swelling. Lastly, scrotal edema secondary to hypoalbuminemia, portal hypertension and lymphadenopathy are also rare but significant conditions that may occur under the aegis of the acute scrotum. In most of these conditions, the history of a slowly progressive disease process helps differentiate them from more classically acute conditions. Treatment of the underlying, non-scrotal cause is most effective to relieve the scrotal symptoms.

Inguinal Hernia

An acute inguinal hernia may also present as an acute scrotum. In this case, pain and swelling involve both the scrotal contents and the groin area. Although important to differentiate, it may be difficult to distinguish an incarcerated inguinal hernia from other, less emergent, scrotal issues such as hydrocele, scrotal trauma, or scrotal abscess. An incarcerated inguinal hernia involves bowel that is obstructed and is a true surgical emergency. In selected, less acute cases, groin and scrotal ultrasound or pelvic CT scans can clarify the diagnosis before surgical exploration. Hernia repairs that use polypropylene mesh for correction may be associated with vas deferens obstruction and infertility later on.

Acute on Chronic Events

Other scrotal conditions that are chronic in nature can also present with acute symptoms and include testicular neoplasms, spermatocele and hydrocele. In the case of testis tumors, patients may only become aware of the mass after it has been present for many months, after it affects the appearance of the scrotum. However, testicular tumors can present precipitously if they undergo hemorrhage or necrosis, and produce swelling, pain and soreness. In this case, a scrotal physical examination reveals a firm, intratesticular mass and scrotal ultrasound demonstrates a solid intratesticular mass which has a > 90% likelihood of being a germ cell tumor. The suspicion of tumor is important for the approach to exploratory surgery in the acute scrotum, as the correct surgical approach to testis cancer is through an inguinal incision and not transcrotally. In addition, the testis and its investments are dissected out intact, to minimize tumor spillage during surgery and spermatic cord ligation is done in the inguinal region to further contain the spread of cancer.

Other chronic scrotal lesions which can present acutely include hydroceles (increased fluid within the tunical vaginalis space) and spermatoceles (cystic dilation of the fine ducts that lead from the rete testis to the epididymal head) that hemorrhage after trauma, or become infected. In addition, a scrotal varicocele, a condition characterized by dilated pampiniform plexus veins and that occurs in 15% of men at puberty, can be present for years but become acutely symptomatic. These dilated veins surround the spermatic cord. If the varicocele has acute onset, is only right-sided, or persists in the supine position, then inferior vena caval (IVC) obstruction must be excluded (i.e., IVC thrombus, abdominal mass, etc). A careful history, physical examination and ultrasound examination is usually sufficient to diagnose these usually benign acute on chronic events. Urgent surgical intervention is rarely needed for drainage of a loculated infection or for a persistent hemorrhage associated with hydroceles or spermatoceles.

Summary

- A full range of scrotal pathology must be considered in acute scrotum cases.
- Several conditions that result in acute scrotum require surgical exploration, making this a very time sensitive condition.
- A high value is place on the history, physical examination and ultrasound imaging for acute scrotum diagnoses.

References:

Meacham RB: Potential for vasal occlusion among men after hernia repair using mesh. J Andrology (2002)23:759-761.

Joyner B & Walsh T: Evaluation of the Pediatric Patient with a Non-Traumatic Acute Scrotum: AUA Update Series (2005), Volume 25, Lesson 12.

Kim SH et al.: Significant predictors for determination of testicular rupture on sonography: a prospective study. J Ultrasound Med.(2007)26:1649-1655.

Lin EP et al.: Testicular torsion: twists and turns. Semin Ultrasound CT MR. (2007)4:317-328.

Tracy CR et al.: Diagnosis and management of epididymitis. Urol Clin North Amer (2008)35:101-108.

Morey AF, Brandes S, Dugi DD, 3rd, Armstrong JH, Breyer BN, Broghammer JA, et al. Urotrauma: AUA guideline. J Urol. 2014;192(2):327-35.

Authors

Seth Cohen, MD

Arcadia, CA

Disclosures: WebMD, Health Publishing; American Urogynecologic Society, Leadership Position; MicrobeDx, Consultant or Advisor

William Gans, MD

West Palm Beach, FL

Disclosures: Opko, Investment Interest

Bruce Slaughenhaupt, MD

Madison, WI

Disclosures: Nothing to disclose

[DONATE](#)

[CONTACT](#)

[PRESS/MEDIA](#)

[SECTIONS](#)

[UROLOGY CARE FOUNDATION](#)

[DIDUSCH MUSEUM](#)

[TERM OF USE](#)

[PRIVACY POLICY](#)

© 2016 American Urological Association Education and Research Inc. All Rights Reserved.